

Tox-positive *Corynebacterium ulcerans* in hedgehogs, Germany

Anja Berger, Alexandra Dangel, Martin Peters, Kristin Mühldorfer, Silke Braune, Tobias Eisenberg, Claudia A. Szentiks, Jörg Rau, Regina Konrad, Stefan Hörmansdorfer, Nikolaus Ackermann & Andreas Sing

To cite this article: Anja Berger, Alexandra Dangel, Martin Peters, Kristin Mühldorfer, Silke Braune, Tobias Eisenberg, Claudia A. Szentiks, Jörg Rau, Regina Konrad, Stefan Hörmansdorfer, Nikolaus Ackermann & Andreas Sing (2019) *Tox*-positive *Corynebacterium ulcerans* in hedgehogs, Germany, *Emerging Microbes & Infections*, 8:1, 211-217, DOI: [10.1080/22221751.2018.1562312](https://doi.org/10.1080/22221751.2018.1562312)

To link to this article: <https://doi.org/10.1080/22221751.2018.1562312>



© 2019 The Author(s). Published by Informa UK Limited, trading as Taylor & Francis Group, on behalf of Shanghai Shangyixun Cultural Communication Co., Ltd



Published online: 21 Jan 2019.



Submit your article to this journal [↗](#)



Article views: 737



View related articles [↗](#)



View Crossmark data [↗](#)



Citing articles: 2 View citing articles [↗](#)



Tox-positive *Corynebacterium ulcerans* in hedgehogs, Germany*

Anja Berger^{a,b†}, Alexandra Dangel^{b†}, Martin Peters^c, Kristin Mühldorfer^d, Silke Braune^e, Tobias Eisenberg^f, Claudia A. Szentiks^d, Jörg Rau^g, Regina Konrad^b, Stefan Hörmansdorfer^b, Nikolaus Ackermann^b and Andreas Sing^{a,b}

^aNational Consiliary Laboratory for Diphtheria, Oberschleißheim, Germany; ^bMA DTM&H, National Consiliary Laboratory for Diphtheria, Bavarian Health and Food Safety Authority, Oberschleißheim, Germany; ^cChemisches und Veterinäruntersuchungsamt Westfalen, Arnsberg, Germany; ^dLeibniz Institute for Zoo and Wildlife Research, Berlin, Germany; ^eLower Saxony State Office for Consumer Protection and Food Safety, Food and Veterinary Institute, Hannover, Germany; ^fHessian State Laboratory (LHL), Gießen, Germany; ^gChemisches und Veterinäruntersuchungsamt Stuttgart, Fellbach, Germany

ABSTRACT

Toxigenic *Corynebacterium ulcerans* may cause both respiratory and cutaneous diphtheria in humans. As a zoonotic emerging pathogen it has been isolated from a wide variety of animals living in captivity, such as livestock, pet, zoo and research animals and additionally in a large number of different wild animals. Here we report the isolation of tox-positive *C. ulcerans* in four hedgehogs with cutaneous diphtheria and pneumonia, respectively.

ARTICLE HISTORY Received 17 December 2018; Accepted 17 December 2018

KEYWORDS Tox-positive; *Corynebacterium*; ulcerans; hedgehogs; Germany

Introduction

Diphtheria and diphtheria-like illness are caused by *Corynebacterium* species harbouring the diphtheria toxin (DT) encoding *tox* gene. In recent years, diphtheria-like human infections with toxigenic *Corynebacterium ulcerans* have outnumbered those caused by toxigenic *C. diphtheriae* in many industrialized countries [1–3]. While about 50 years ago human cases of *C. ulcerans*-caused disease were associated with consumption of raw milk and dairy products or contact to cattle [3–5], nearly all *C. ulcerans* infections since then have been described after contact with domestic animals such as pet dogs and cats [3,6–11] or – less often – after occupational contact with livestock animals such as pigs [12,13]. Moreover, both non-toxigenic and toxigenic *C. ulcerans* as emerging zoonotic pathogens have been isolated from a wide variety of animal species, either from zoo, shelter, research or herd animals with human contact, e.g. water rats [14], shelter dogs [15,16], macaques [17,18], killer whales [19], a lion [19], a dromedary [20], ferrets [21], a goat [22], a cow [23] and ground squirrels [24] or from free-roaming animals such as otters [25], roe deer [26,27], wild boars [27,28], red fox [29], Ural owl [30] and Japanese shrew-moles [30] (Table 1). Interestingly, most of the toxigenic *C. ulcerans* strains were found either in

carnivores or animals with (seasonal) group hierarchical fighting. Here we report on the unusual finding of toxigenic *C. ulcerans* in four hedgehogs (*Erinaceus europaeus*), three of them without known previous contact to humans.

Results

In December 2017, a young hedgehog (#1) was found with a weight of 1026 g in a garden with severe soft tissue damage after being cut by a mowing machine (Figure 1(a)). The injured animal was brought to a local veterinarian and treated for 12 days with enrofloxacin and a proteinolytic ointment. Because of an extremely retarded wound healing and severe loss of weight the animal was transferred to a private hedgehog rescue station in March 2018, where the animal (750 g) was presented to another veterinarian and taken care of. A wound swab was taken for bacteriological diagnosis. The animal was treated with a third generation cephalosporin which was later switched to sulphonamides for 10 days. The wound continued to heal within three months (Figure 1(b,c)) with diminishing necrotic wound margins.

In April 2017, a male hedgehog (#2) was found in an allotment colony in Berlin, Germany, in a moribund condition. The animal died and was subjected to

CONTACT Andreas Sing ✉ andreas.sing@lgl.bayern.de National Consiliary Laboratory for Diphtheria, 85764 Oberschleißheim, Germany; MA DTM&H, National Consiliary Laboratory for Diphtheria, Bavarian Health and Food Safety Authority, 85764 Oberschleißheim, Germany

*This article is dedicated to Professor Dr Hubertus Brunn, the longstanding director of the Hessian State Laboratory (LHL), in honor of his retirement.

[†]Both authors contributed equally to this paper.

Supplemental data for this article can be accessed at <https://doi.org/10.1080/22221751.2018.1562312>

© 2019 The Author(s). Published by Informa UK Limited, trading as Taylor & Francis Group, on behalf of Shanghai Shangyixun Cultural Communication Co., Ltd
This is an Open Access article distributed under the terms of the Creative Commons Attribution License (<http://creativecommons.org/licenses/by/4.0/>), which permits unrestricted use, distribution, and reproduction in any medium, provided the original work is properly cited.

Table 1. Characteristics of *Corynebacterium ulcerans* isolated from free-roaming wild animals.

Animal species	Number	Country	Clinical manifestation	Source	Toxigenicity	Reference
Otter (<i>Lutra lutra</i>)	2	Great Britain (Scotland and England)	Found dead; lung damage	Lung biopsies	Toxigenic	[25]
Roe deer (<i>Capreolus capreolus</i>)	1	Southern Germany	Abscess	Abscess material	NTTB	[26,27]
Wild boar (<i>Sus scrofa</i>)	12	Southern, Western and North-Eastern Germany	Abscesses and enlarged lymph nodes	Abscess and/or lymph node material	NTTB	[27,28]
Red fox (<i>Vulpes vulpes</i>)	1	Southern Germany	Distemper	Splenic tissue	Toxigenic	[29]
Ural owl (<i>Strix uralensis</i>)	1	Japan	Asymptomatic	Throat swab	Toxigenic	[30]
Japanese shrew-mole (<i>Urotrichus talpoides</i>)	2	Japan	Asymptomatic	Throat swab	Toxigenic	[30]
Hedgehog (<i>E. europaeus</i>)	1	Western Germany	Deep soft tissue wound	Wound swab	Toxigenic	Current paper
Hedgehog (<i>E. europaeus</i>)	3	Eastern and Northern Germany	Pneumonia, bacteriemia	Lung tissue, heart tissue	1 NTTB 2 toxigenic	Current paper

NTTB non-toxicogenic *tox*-bearing.

necropsy showing a weight of 570 g but considering the adipose tissue still had a good nutritional status. Gross pathological examination revealed otitis externa (left ear), anaemia and severe tick infestation. Thickening and redness of the lung suggestive of pneumonia were observed prompting further histological and bacteriological investigations.

In July 2018 two hedgehogs (#3 and #4) were found in Hanover, Germany and finally euthanized because of moribund conditions. Both were adult, male animals with a weight of 760 and 605 g, respectively.



(a)



(b)

Figure 1. (a,b) Wound infection due to toxigenic *C. ulcerans* in a hedgehog, healing progress under antibiotic treatment.

Pathological examination revealed myiasis and otitis externa in both cases. Further histological and bacteriological investigations were done because of gross pathological aspects of severe pneumonia and septicaemia in both cases. None of the four hedgehogs presented typical local or systemical findings of diphtheria toxin effects such as pseudomembranes or histopathological lesions indicating myocarditis or damage of the peripheral nervous system.

The wound swab obtained from the severe soft tissue wound of hedgehog #1 grew *C. ulcerans* (strain number KL 1151) and *Streptococcus pyogenes*. Toxigenicity was verified by real-time PCR and a modified Elek test both yielding positive results. Histopathological examination of lung tissues of hedgehogs #2, #3 and #4 showed pneumonia and a severe lungworm infection in hedgehog #2, respectively. Lung tissue material obtained from hedgehog #2 grew *C. ulcerans* (strain number KL 955) in pure culture. Toxigenicity testing by *tox*-PCR and Elek identified the isolate as non-toxicogenic *tox*-bearing (NTTB). Lung and heart tissue material obtained from hedgehog #3 grew *Enterococcus avium*, *Morganella morganii* and *C. ulcerans* (KL 1203). *C. ulcerans* strain KL 1204 was isolated in pure culture from heart and lung tissue materials obtained from hedgehog #4. Both KL 1203 and KL 1204 were toxigenic as shown by positive *tox*-PCR and Elek testing, respectively. All *C. ulcerans* were identified by partial *rpoB* sequencing, FT-IR and MALDI-TOF analysis.

Commercially available biochemistry systems unequivocally identified all four isolates as *C. ulcerans* (VITEK, Omnilog) with the exception of isolate KL 955 which was falsely identified as *C. pseudotuberculosis* by VITEK CBC. All isolates were found to be resistant against penicillin (MICs 0.19–0.25 mg/l) and clindamycin (MICs 2–4 mg/l) according to EUCAST, but susceptible against erythromycin, cephalosporins and sulphonamides according to CLSI guidelines. NGS-derived MLST based on seven housekeeping loci was performed using NGS data and revealed three different sequence types (ST), 332 in hedgehog #1 (KL 1151) and hedgehog #4 (KL

1204), ST 330 in hedgehog #2 (KL 955), and ST 331 in hedgehog #3 (KL 1203), respectively.

Phylogenetic minimum spanning trees, built from cgMLST results of NGS data showed that the genetic similarity of the four *C. ulcerans* isolates from hedgehogs was much lower to the NTTB wildlife cluster from wild boars and roe deer (>1000 alleles) than to human samples from different geographic regions (>200 alleles). However, genomic differences in cgMLST analysis were at least 73 alleles between isolates from hedgehog #1 and #4 which shared the same ST 332 based on the 7-gene scheme and more than 200 alleles compared to all other isolates. These differences show that the hedgehog-derived isolates are genetically not closely related to each other or to any other human or animal isolate (Figure 2(a,b)).

The comparison of FT-IR spectra (Figure 3) shows no similarity for the four hedgehog isolates with the NTTB wildlife cluster (wild boars, roe deer) observed in different parts of Germany [26–28].

Discussion

In contrast to the classical diphtheria agent *C. diphtheriae* which is basically a human pathogen and has only extremely rarely been reported to be isolated from animals [32], the emerging pathogen *C. ulcerans* is a zoonotic pathogen with an increasing spectrum of affected animals. While originally only reported from livestock (cattle, pigs) and pet (dog, cat) animals, *C. ulcerans* has been meanwhile detected in a wide variety of species living in captivity as zoo (killer whales, lion, water rats), shelter (dogs), herd (dromedary, goat, cow) or research (macaques, ground squirrels) animals with contact to humans. In recent years, isolation of *C. ulcerans* has also been reported in wildlife (Table 1). Interestingly, the broad majority

of wild animals affected by *C. ulcerans* showed pathologic lesions of internal organs such as lymph nodes [26–28], lung [25] – also in hedgehogs #2, #3 and #4 of the current study – or spleen [29] suggesting systemic infection. These findings are in contrast to human diphtheria cases due to *C. diphtheriae* or *C. ulcerans* exhibiting respiratory or cutaneous manifestations or to *C. ulcerans* infections in animals living in captivity which were reported to be either asymptomatic carriers or to present with skin or mucosal ulceration. One could assume that only wild animals with a deteriorating disease, possibly aggravated by *C. ulcerans* infection are found and diagnosed, while the asymptomatic carriage of *C. ulcerans* in wildlife is likely as usual as in other animals. Asymptomatic pharyngeal carriage is known for *C. diphtheriae* and – rarely – *C. ulcerans* in humans, but also for *C. ulcerans* primarily in pets and less frequently in livestock animals. In wildlife, however, it has so far only been reported in a recent surveillance study among wild birds and their prey animals [30]. Most reported *C. ulcerans* strains in animals – both with and without human contact – harbour the *tox* gene [10]. Further studies are needed to determine if this is only a reporting bias or reflects the real distribution of toxigenic and non-toxigenic *C. ulcerans* strains among animals and also humans. Since DT producing strains among wild animals were until very recently detected only in carnivores (otters, red fox, Ural owl) with non-toxigenic strains isolated from omnivorous (e.g. wild boars) and herbivorous (e.g. roe deer) animals, it seemed possible that *C. ulcerans* toxigenicity might be associated with a carnivorous lifestyle involving predatory hunting behaviour with the potential of acquiring an infection while fighting. However, the recent detection of asymptomatic carriage of toxigenic *C. ulcerans* in two Japanese shrew-moles [30], as well as the current

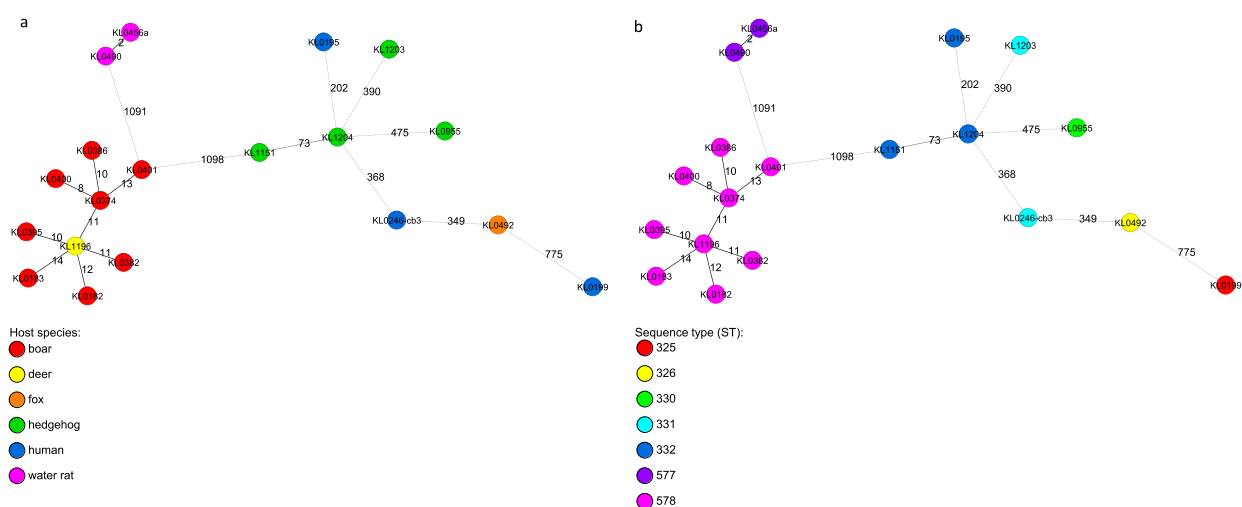


Figure 2. (a,b) Phylogenetic minimum spanning trees of the cgMLST analysis of 19 *C. ulcerans* isolates originating from various host species with an in-house *C. ulcerans*-specific cgMLST scheme of 1211 target loci. Allele distances between samples are indicated. Samples are colour coded by the corresponding host organism (A) or by their ST based on the 7-gene scheme (B), as given in the legend.

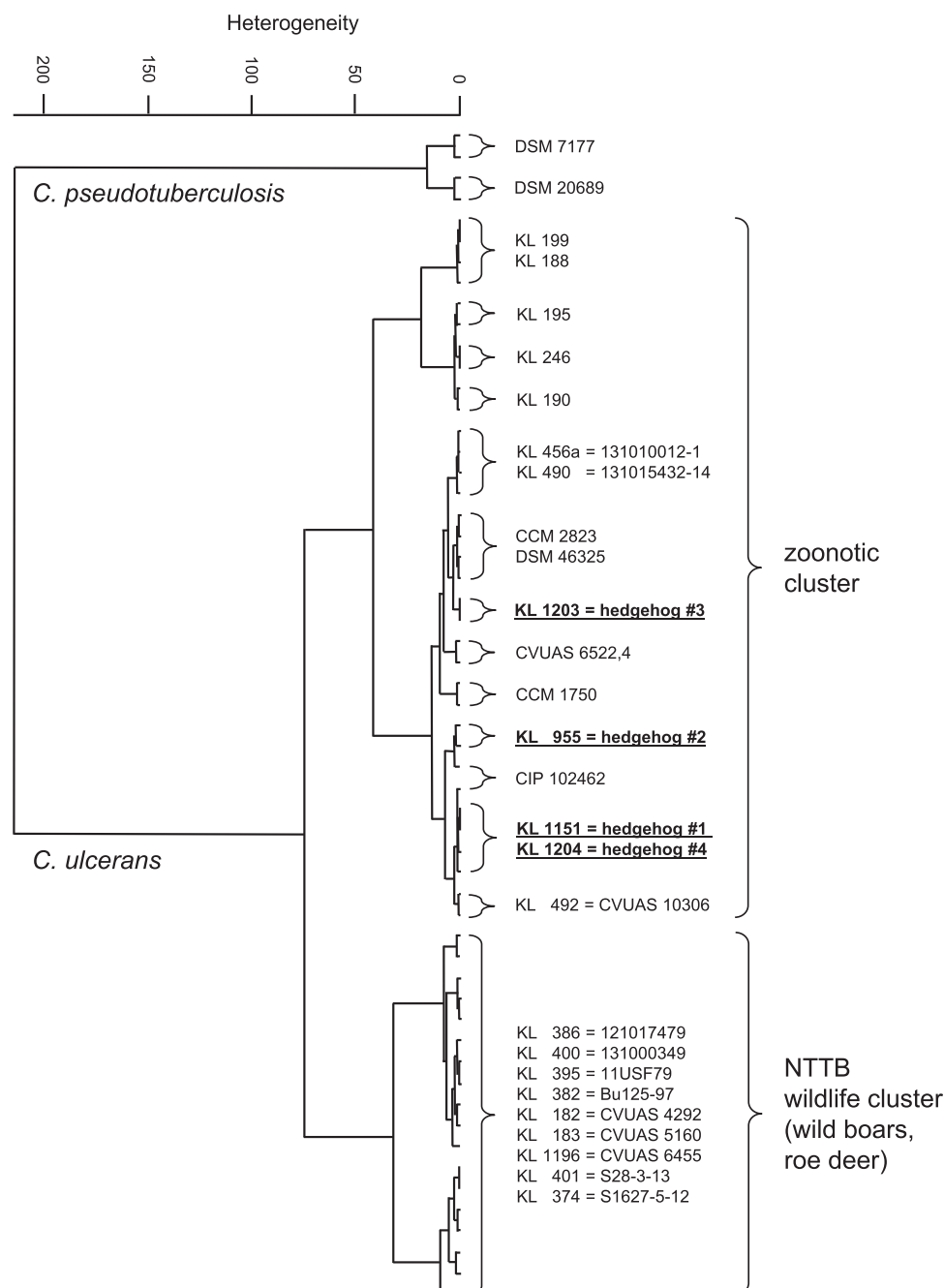


Figure 3. Dendrogram of FT-IR-spectra of *C. ulcerans* strains obtained from the four hedgehogs (underlined) in comparison with spectra from *C. ulcerans* DSM 46325 and several *C. ulcerans* isolates, including isolates from wild animals and humans in Germany. Spectra of two *C. pseudotuberculosis* strains are used as outgroup.

cases of hedgehogs (this study), broadens the spectrum of affected animals also to primarily insectivorous species.

In contrast to the majority of reported *C. ulcerans* infections in humans causing cutaneous diphtheria [33] as well as in pet or livestock animals [3] with mucosal or skin involvement, superficial soft tissue infection in wild animals has so far only been reported in the current hedgehog #1. Similar to most cases of human cutaneous *C. diphtheriae*-caused diphtheria the infection in hedgehog #1 was associated with a previous trauma, but the source of *C. ulcerans* remains unclear. The strain might be acquired from the environment, an anatomical site of the hedgehog,

during its stay in the hedgehog rescue station or from another carnivorous animal trying to feed on the heavily injured hedgehog. However, no signs of animal-afflicted bite wounds were noticed. In hedgehog #3 and #4 otitis externa induced by myiasis could possibly be the portal of entry for the *C. ulcerans* strains.

Notably, according to the recently revised German recommendations [31], public health measures including personal protection, antibiotic prophylaxis and screening for *C. ulcerans* carriage for close contact persons were advised, since zoonotic transmission from pet animals to humans has been clearly demonstrated using molecular typing techniques [6,8–12]. The analysed dataset also indicates closer genetic similarity of

the hedgehog-derived isolates to human isolates than to those from wild animals, although no close relationship of the hedgehog isolates to any other isolate was detected. However, *C. ulcerans* carrier status of persons with direct contact to hedgehogs was not a subject of the investigation. As a bacteriological examination with detection of *C. ulcerans* was performed after intensive care treatment of hedgehog #1, all close contact persons refused recommended measures and only engaged in hygienic behaviour and self-observation for clinical signs of diphtheria, raising the general awareness of zoonotic agents in wildlife care. Toxigenic *C. ulcerans* harbour either prophages or, an alternative pathogenicity island (PAI) described previously and can therefore act as a beta corynebacterium reservoir [10].

In conclusion, the finding of toxigenic *C. ulcerans* in hedgehogs, an increasingly synanthropic species known to reside in urban and suburban environments in close proximity to humans, highlights potential transmission risks and should raise the public health awareness towards zoonotic infections.

Material and methods

For bacteriological examination, clinical material obtained from all four animals (i.e. wound swabs and lung or heart tissue, respectively) were plated on Columbia agar with 5% sheep blood, chocolate agar supplemented with Vitox (5% CO₂ atmosphere) and Gassner agar (Oxoid, Wesel, Germany) and incubated for up to 48 hours at 37 °C. Bacteriological species identification was performed as recently described [34] using MALDI-TOF MS analysis (Microflex LT Mass Spectrometer, MALDI Biotyper™; Bruker Daltonics, Bremen, Germany) and the MBT 7311 commercial library. Supplementary species identification by commercial biochemistry assays (VITEK2-compact with card systems for anaerobes and corynebacteria [ANC] and coryneform bacteria [CBC; all bioMérieux, Nürtingen, Germany] and Omnilog [Biolog, Hayward, USA]) was done according to the manufacturers prescriptions. Fourier-transform infrared (FT-IR) spectroscopy with cluster analysis, and partial sequencing of the *rpoB* gene were carried out as described previously [27,28,35]. Toxigenicity was investigated by real-time PCR [36] and a modified Elek test [37]. Next-generation sequencing (NGS) of the isolates was performed on an Illumina MiSeq (Illumina, San Diego, CA, USA) as reported previously [38]. Multilocus sequence typing (MLST) based on seven house-keeping loci [39] was done using the NGS data. The sequence type (ST) was determined with the respective MLST database (<http://pubmlst.org/cdiphtheriae/>). For cg (core genome) MLST typing an ad-hoc *C. ulcerans*-specific cgMLST scheme was generated by using the SeqSphere+ target definer tool (Ridom, Munster, Germany) with default settings [40]. As a reference,

the genome of strain 809 with accession number NC_018101 was used. 11 complete *C. ulcerans* genomes from NCBI were used as query sequences for core genome scheme definition (accession nos. NC_018101.1, NZ_CP009716.1, NZ_CP010818.1, NZ_CP011095.1, NZ_CP009583.1, NZ_CP009500.1, NC_015683.1, NZ_CP009622.1, NZ_CP011913.1, NZ_LT906443.1, NZ_CP021417.1). The resulting cgMLST scheme consisted of 1,211 target loci. cgMLST with the described ad-hoc scheme was performed using NGS data as described [38]. NGS raw datasets are available in the NCBI sequence read archive (SRA) at <https://www.ncbi.nlm.nih.gov/sra> (accession numbers in Supplementary Table 1). Antibiotic susceptibility testing was performed according to both CLSI (CLSI: Performance standards for antimicrobial susceptibility testing. M100, 28th. Ed., Jan 2018;

CLSI: Methods for Antimicrobial Dilution and Disk Susceptibility Testing of infrequently isolated or fastidious bacteria. M45 3rd Ed, 2015) and EUCAST guidelines (http://www.eucast.org/clinical_breakpoints, version 8.1).

For histopathological examination, small slices of lung tissue were fixed in 4% buffered formalin, processed using standard methods and embedded in liquid paraffin. Sections were stained with hematoxylin-eosin (HE).

Summary of the conclusions

The first isolation of *tox*-positive *Corynebacterium ulcerans* from four hedgehogs underlines both the veterinary and the human public health importance of a variety of wild animals which might serve as zoonotic *C. ulcerans* reservoirs for pet or livestock animals and humans.

Acknowledgements

We thank Wolfgang Schmidt, Sabine Wolf, Marion Linder-mayer, Katja Meindl, Jasmin Fräßdorf, Vanessa Nowak, Martin Dyk, Nadine Jahn, Zoltan Mezö, Sabine Schiller and Anna Eckert for excellent technical assistance. AB, MP, KM, SB, TE, CAS, RK, SH, NA and AS were involved in primary bacteriological and histopathological diagnostics, RK performed PCRs, AB and AS performed special diagnostics for diphtheria, AD performed the NGS analysis, JR performed the FT-IR analysis. All authors participated in conducting the study and in writing the paper.

Disclosure statement

No potential conflict of interest was reported by the authors.

Funding

The study was partly supported by the Bavarian State Ministry of Health and Care as well as by the German Federal Ministry of Health via the Robert Koch-Institute and its National Reference Laboratories Network (09-47, FKZ

1369–359). The work was done as part of our involvement in the European Study Group of Public Health Microbiology (ESGPHM) of the European Society of Clinical Microbiology and Infectious Diseases (ESCMID).

References

- [1] Bonmarin I, Guiso N, Le Flèche-Matéos A, et al. Diphtheria: a zoonotic disease in France? *Vaccine*. 2009;27:4196–4200.
- [2] Wagner KS, White JM, Crowcroft NS, et al. Diphtheria in the United Kingdom, 1986–2008: the increasing role of *Corynebacterium ulcerans*. *Epidemiol Infect*. 2010;138:1519–1530.
- [3] Hacker E, Antunes CA, Mattos-Guaraldi AL, et al. *Corynebacterium ulcerans*, an emerging human pathogen. *Future Microbiol*. 2016;11:1191–1208.
- [4] Bostock AD, Gilbert FR, Lewis D, et al. *Corynebacterium ulcerans* infection associated with untreated milk. *J Infect*. 1984;9:286–288.
- [5] Hart RJ. *Corynebacterium ulcerans* in humans and cattle in North Devon. *J Hyg*. 1984;92:161–164.
- [6] Lartigue MF, Monnet X, Le Fleche A, et al. *Corynebacterium ulcerans* in an immunocompromised patient with diphtheria and her dog. *J Clin Microbiol*. 2005;43:999–1001.
- [7] Hogg RA, Wessels J, Hart J, et al. Possible zoonotic transmission of toxigenic *Corynebacterium ulcerans* from companion animals in a human case of fatal diphtheria. *Vet Rec*. 2009;165:691–692.
- [8] Berger A. Toxigenic *Corynebacterium ulcerans* in woman and cat. *Emerg Infect Dis*. 2011;17:1767–1769.
- [9] Meinel DM, Konrad R, Berger A, et al. Zoonotic transmission of toxigenic *Corynebacterium ulcerans* strain, Germany, 2012. *Emerg Infect Dis*. 2015;21:356–358.
- [10] Meinel DM, Margos G, Konrad R, et al. Next generation sequencing analysis of nine *Corynebacterium ulcerans* isolates reveals zoonotic transmission and a novel putative diphtheria toxin-encoding pathogenicity island. *Genome Med*. 2014;6:113.
- [11] Vandentorren S, Guiso N, Badell E, et al. Toxigenic *Corynebacterium ulcerans* in a fatal human case and her feline contacts, France, March 2014. *Euro Surveill*. 2014;19:20910.
- [12] Schuëgger R, Schoerner C, Dlugaičzyk J, et al. Pigs as source for toxigenic *Corynebacterium ulcerans*. *Emerg Infect Dis*. 2009;15:1314–1315.
- [13] Berger A, Boschert V, Konrad R, et al. Two cases of cutaneous diphtheria associated with occupational pig contact in Germany. *Zoonoses Public Health*. 2013;60:539–542.
- [14] Eisenberg T, Mauder N, Contzen M, et al. Outbreak with clonally related isolates of *Corynebacterium ulcerans* in a group of water rats. *BMC Microbiol*. 2015;15:42.
- [15] Katsukawa C, Komiya T, Yamagishi H, et al. Prevalence of *Corynebacterium ulcerans* in dogs in Osaka, Japan. *J Med Microbiol*. 2012;61:266–273.
- [16] Dias AA, Silva FC, Pereira GA, et al. *Corynebacterium ulcerans* isolated from an asymptomatic dog kept in an animal shelter in the metropolitan area of Rio de Janeiro, Brazil. *Vector Borne Zoonotic Dis*. 2010;10:743–748.
- [17] Fox JG, Frost WW. *Corynebacterium ulcerans* mastitis in a bonnet macaque (*Macaca radiata*). *Lab Anim Sci*. 1974;24:820–822.
- [18] Venezia J, Cassiday PK, Marini RP, et al. Characterization of *Corynebacterium* species in macaques. *J Med Microbiol*. 2012;61:1401–1408.
- [19] Seto Y, Komiya T, Iwaki M, et al. Properties of corynebophage attachment site and molecular epidemiology of *Corynebacterium ulcerans* isolated from humans and animals in Japan. *Jpn J Infect Dis*. 2008;61:116–122.
- [20] Tejedor MT, Martin JL, Lupiola P, et al. Caseous lymphadenitis caused by *Corynebacterium ulcerans* in the dromedary camel. *Can Vet J*. 2000;41:126–127.
- [21] Marini RP, Cassiday PK, Venezia J, et al. *Corynebacterium ulcerans* in Ferrets. *Emerg Infect Dis*. 2014;20:159–161.
- [22] Morris WE, Uzal FA, Cipolla AL. Pyogranulomatous meningoencephalitis in a goat due to *Corynebacterium ulcerans*. *Vet Rec*. 2005;156:317–318.
- [23] Murakami K, Hata E, Hatama S, et al. Eosinophilic granuloma with Splendore-Hoeppli material caused by toxigenic *Corynebacterium ulcerans* in a heifer. *J Vet Med Sci*. 2014;76:931–935.
- [24] Olson ME, Goemans I, Bolingbroke D, et al. Gangrenous dermatitis caused by *Corynebacterium ulcerans* in Richardson ground squirrels. *J Am Vet Med Assoc*. 1988;193:367–368.
- [25] Foster G, et al. *Corynebacterium ulcerans* in free-ranging otters. *Vet Rec*. 2002;150:524.
- [26] Rau J, Blazey B, Contzen M, et al. *Corynebacterium ulcerans* infection roe deer (*Capreolus capreolus*). *Berl Münch Tierärztl Wschr*. 2012;125:159–162.
- [27] Eisenberg T, Kutzer P, Peters M, et al. Nontoxigenic tox-bearing *Corynebacterium ulcerans* infection among game animals, Germany. *Emerg Infect Dis*. 2014;20:448–452.
- [28] Contzen M, Sting R, Blazey B, et al. *Corynebacterium ulcerans* from diseased wild boars. *Zoonoses Public Health*. 2011;58:479–488.
- [29] Sting R, Ketterer-Pintur S, Contzen M, et al. Toxigenic *Corynebacterium ulcerans* isolated from a free-roaming red fox (*Vulpes vulpes*). *Berl Munch Tierärztl Wochenschr*. 2015;128:204–208.
- [30] Katsukawa C, Umeda K, Inamori I, et al. Toxigenic *Corynebacterium ulcerans* isolated from a wild bird (Ural owl) and its feed (shrew-moles): comparison of molecular types with human isolates. *BMC Res Notes*. 2016;9:181.
- [31] RKI: Ratgeber für Ärzte – Diphtherie https://www.rki.de/DE/Content/Infekt/EpidBull/Merkblaetter/Ratgeber_Diphtherie.html
- [32] Sing A, Konrad R, Meinel DM, et al. *Corynebacterium diphtheriae* in a free-roaming red fox: case report and historical review on diphtheria in animals. *Infection*. 2016;44:441–445.
- [33] Moore LSP, Leslie A, Meltzer M, et al. *Corynebacterium ulcerans* cutaneous diphtheria. *Lancet Infect Dis*. 2015;15:1100–1107.
- [34] Konrad R, Berger A, Huber I, et al. Matrix-assisted laser desorption/ionisation time-of-flight (MALDI-TOF) mass spectrometry as a tool for rapid diagnosis of potentially toxigenic *Corynebacterium* species in the laboratory management of diphtheria-associated bacteria. *Euro Surveill*. 2010;15:19699.
- [35] Khamis A, Raoult D, La Scola B. Comparison between *rpoB* and 16S rRNA gene sequencing for molecular identification of 168 clinical isolates of *Corynebacterium*. *J Clin Microbiol*. 2005;43:1934–1936.
- [36] Schuëgger R, Lindermayer M, Kugler R, et al. Detection of toxigenic *Corynebacterium diphtheriae*

- and *Corynebacterium ulcerans* strains by a novel real-time PCR. J Clin Microbiol. [2008](#);46:2822–2823.
- [37] Engler KH, Glushkevich T, Mazurova IK, et al. A modified Elek test for detection of toxigenic corynebacteria in the diagnostic laboratory. J Clin Microbiol. [1997](#);35:495–498.
- [38] Dangel A, Berger A, Konrad R, et al. Geographically diverse clusters of nontoxigenic *Corynebacterium diphtheriae* infection, Germany, 2016–2017. Emerg Infect Dis. [2018](#);24:1239–1245.
- [39] König C, Meinel DM, Margos G, et al. Multilocus sequence typing of *Corynebacterium ulcerans* provides evidence for zoonotic transmission and for increased prevalence of certain sequence types among toxigenic strains. J Clin Microbiol. [2014](#);52:4318–4324.
- [40] Ruppitsch W, Pietzka A, Prior K, et al. Defining and evaluating a core genome multilocus sequence typing scheme for whole-genome sequence-based typing of *Listeria monocytogenes*. J Clin Microbiol. [2015](#);53:2869–2876.