

Received: 2022.01.31
Accepted: 2022.06.08
Available online: 2022.06.17
Published: 2022.07.26

Pneumocystis jirovecii Pneumonia with a Normal Early Chest Radiography and Complicated with Drug-Induced Immune Hemolytic Anemia: A Case Report

Authors' Contribution:
Study Design A
Data Collection B
Statistical Analysis C
Data Interpretation D
Manuscript Preparation E
Literature Search F
Funds Collection G

ABCDEF **Norbainun Che Hamid**
ACEF **Khasnur Abd Malek**
DE **Nafiza Mat Nasir**
DEF **Nik Munirah Nasir**

Department of Primary Care Medicine, Faculty of Medicine, Universiti Teknologi MARA, Sungai Buloh, Selangor, Malaysia

Corresponding Author: Khasnur Abd Malek, e-mail: drkhasnurabdmalek@gmail.com
Financial support: None declared
Conflict of interest: None declared

Patient: **Male, 39-year-old**
Final Diagnosis: ***Pneumonitis Jirovecii* pneumonia**
Symptoms: **Anaemia • chills • fever • shortness of breath • tachypnea • weight loss**
Medication: —
Clinical Procedure: —
Specialty: **Infectious Diseases**





Objective: **Unusual clinical course**
Background: *Pneumocystis jirovecii* pneumonia (PJP) is an opportunistic infection that commonly occurs in immunocompromised patients, especially those with HIV. Early diagnosis and prompt treatment are important because PJP is a potentially life-threatening infection. However, the diagnosis of PJP in the early stage can be challenging due to various factors. Furthermore, the early presentation of PJP, which includes normal chest radiograph and examination findings along with the subacute presentation of PJP in patients with HIV, makes an early diagnosis of the disease even more challenging for doctors.

Case reports: In this case report, we present the case of a 39-year-old man who had normal chest X-ray findings during the initial stage of his presentation. Coupled with non-disclosure of HIV status, these led to a delay in PJP diagnosis. The diagnosis of PJP with underlying HIV was later supported by the patient's clinical features, initial blood investigations, and presence of high-risk sexual activity. The diagnosis was confirmed when the PJP polymerase chain reaction test from the respiratory sample was positive. He was successfully treated with oral trimethoprim-sulfamethoxazole. However, he subsequently developed rare adverse effects of drug-induced immune hemolytic anemia, which was diagnosed based on the presence of hemolytic anemia and recent exposure to a new drug. Trimethoprim-sulfamethoxazole was promptly discontinued, which resulted in symptom improvement.

Conclusions: This case report aims to create awareness among primary care doctors to be vigilant of the PJP diagnosis and its nonspecific presentations as well as to the rare adverse effects of medications to treat PJP.

Keywords: **HIV • Immunocompromised Host • Pneumonia, Pneumocystis**

Full-text PDF: <https://www.amjcaserep.com/abstract/index/idArt/936278>

 1675  1  3  18



Background

Pneumocystis jirovecii pneumonia (PJP) is an opportunistic infection caused by *Pneumocystis jirovecii* [1]. The prevalence of PJP increased tremendously with the emergence of the HIV epidemic in the 1980s [2]. Nonetheless, the incidence of PJP has dramatically declined owing to effective antiretroviral therapy and, to a lesser extent, the use of prophylaxis [3]. The early identification of PJP could be tricky because of the subtle clinical features and normal chest radiographs in one-third of the cases [4]. Furthermore, PJP in HIV-infected patients differs from that in other immunocompromised patients, who usually follow a subacute course with longer symptoms duration [3]. It is important to obtain a definitive diagnosis because PJP treatment entails a lengthy course of potentially toxic therapy [1]. We report a case of a challenging PJP diagnosis due to its indistinguishable features and the patient's failure to disclose an HIV risk factor, which was then further complicated with drug-induced immune hemolytic anemia (DIIHA).

Case Report

A 39-year-old man with no known medical illness presented to the primary care clinic in a tertiary hospital setting with fever and dry cough for 2 weeks and unintentional weight loss of about 10 kg over 1 month. His had a low-grade fever of 37.3°C, which spiked in the evening to 38°C. The fever was associated with night sweats, chills, and rigors. He had never sought treatment before this presentation. There was no history of hemoptysis, shortness of breath, or chest pain. There was no recent travel history, exposure to COVID-19, or tuberculosis close contacts. He was single and denied being sexually active. He was a non-smoker and denied alcohol abuse and the use of illicit drugs.

The physical examination revealed a thin man with no signs of respiratory distress. His oxygen saturation was 98% on room air, and his tympanic temperature was 36.8°C. His other vital signs were normal. The patient did not have a skin rash or petechial, and there was no palpable cervical lymphadenopathy. Auscultation of the lungs revealed normal vesicular breathing with no added sounds, and examination of the other major systems did not yield any contributory information.

Based on the patient's history and that this was a highly endemic region for tuberculosis, a provisional working diagnosis of pulmonary tuberculosis was made. The initial laboratory workup showed a normal white cell count ($5.85 \times 10^9/L$), with lymphopenia (lymphocyte count, $0.89 \times 10^9/L$) and eosinophilia (eosinophil count, $0.92 \times 10^9/L$). His hemoglobin level was low (11.7 g/dL), with a normal mean cell volume (94.4 fl) and normal platelet count ($273 \times 10^9/L$). His erythrocyte sedimentation rate was 73 mm/h. The serum liver function test, renal profile,

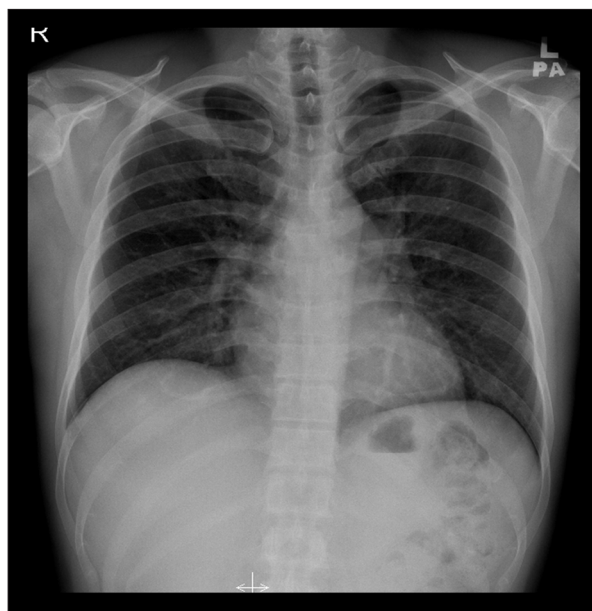


Figure 1. Chest X-Ray on June 30, 2020, showed clear lung fields with no mediastinal widening or hilar lesion.

serum lactate dehydrogenase, and urinalysis were within the reference ranges. Three consecutive sputum samples were negative for acid-fast organisms on staining. A chest X-ray (CXR) revealed a clear lung field with no mediastinal widening or hilar lesion (Figure 1). The abnormalities of initial tests led to expanding differential diagnoses of worm infestation, neoplasm, and HIV. Thus, the history was revisited to assess for any high-risk behavior; however, the patient did not reveal any new information. The patient consented to additional tests, including HIV, viral hepatitis screening, and stool for ova and cyst. The serological tests were positive for HIV 1 and HIV 2, while the hepatitis and stool tests were negative. However, the patient missed his scheduled appointment, and although several attempts were made to call him, he was not reached.

Four days later, the patient was presented to our Emergency Department with worsening shortness of breath and a further weight loss of 5 kg. On examination, the patient was noted to be lethargic and to have tachypnea with a respiratory rate of 25 breaths per min, with oxygen saturation of 85% on room air. His other vital signs were normal: blood pressure was 110/70 mmHg, pulse rate was 95 beats per min, and tympanic temperature was 36.4°C. Auscultation of the lungs revealed crepitations over the right lung. His arterial blood gas on the nasal prong oxygen 3 L/min revealed borderline hypoxemia as follows: pH 7.447, PaO₂ 88.3 mmHg, pCO₂ 33.9 mmHg, and HCO₃ 23.4 mmol/L. His C-reactive protein was elevated at 20.5 mg/dL. His full blood count showed similar findings as the initial test, with normal liver function, renal function, cardiac enzymes, and electrolytes, and a negative D-dimer. The summary of the serial blood investigations is shown in

Table 1. Laboratory investigation at presentation and day 21 while on oral trimethoprim-sulfamethoxazole.

Laboratory test	At presentation	Day 21 while on oral trimethoprim-sulfamethoxazole	Reference range
Hemoglobin	11.7	5.7	(13.0-17.0) g/dL
Mean cell volume	94.4	96.5	(83.0-101.0) fl
Mean cell hemoglobin	29.9	33.1	(27.0-32.0) pg
Hematocrit	36.9	16.6	(40.0-50.0)%
Reticulocyte counts	-	11.4	(0.5-2.5)%
Platelet counts	273	219	(150-410)×10 ⁹ /L
White cell count	5.85	8.84	(4.00-10.00)×10 ⁹ /L
Neutrophil count	3.47	7.93	(2.00-7.00)×10 ⁹ /L
Lymphocyte count	0.89	0.42	(1.00-3.00)×10 ⁹ /L
Eosinophil count	0.92	0.14	(0.02-0.50)×10 ⁹ /L
ESR	73		(1-15) mm/h
Biochemistry			
Urea	3.50		(2.78-8.07) mmol/L
Creatinine	87		(62-106) μmol
Sodium	138		(136-145) mmol/L
Potassium	4.1		(3.5-5.1) mmol/L
Albumin	38.1		(35.0-52.0) g/L
Alkaline phosphatase	63.0		(40.0-130.0) U/L
Alanine transaminase	22.8		<41.0 U/L
CRP	20.5		<5.0 mg/L
Lactate dehydrogenase	215	342 U/L	(135-225) U/L
D-dimer	Negative		<500 ng/mL

ESR – erythrocyte sedimentation rate; CRP – C-reactive protein.

Table 1. An electrocardiogram showed a normal sinus rhythm. The COVID-19 polymerase chain reaction (PCR) test was negative. In comparison with a normal CXR taken 2 weeks prior, his latest CXR revealed some ground-glass opacity areas with reticular changes in a perihilar distribution (**Figure 2**). Besides PJP, other differential diagnoses based on CXR findings were viral pneumonia (COVID-19), eosinophilic pneumonia, and other opportunistic infections, such as cytomegalovirus pneumonitis. The PCR test for PJP was positive. Further tests revealed a baseline CD4 cell count of 28 cells/μL. At this presentation, the patient finally admitted to having a history of unprotected sexual encounters with multiple partners before becoming ill.

A diagnosis of PJP was made, and the patient started on oral trimethoprim-sulfamethoxazole 2400 mg 3 times a day and

an oral prednisolone tapering regime: 40 mg every 12 h for 5 days, 40 mg every 24 h for 5 days, and 20 mg every 24 h for 11 days. This resulted in the improvement of general conditions, abatement of fever and dyspnea, and reduction in oxygen support in 1 week. Unfortunately, 3 weeks after starting the trimethoprim-sulfamethoxazole, the patient's hemoglobin dropped from 11 g/dL to 5.7 g/dL, with a high reticulocyte count of 11.4% and high serum lactate dehydrogenase (342 U/L). The white blood cell and platelet counts remained normal. His peripheral blood film showed numerous microspherocytes. The serum haptoglobin and serum unconjugated bilirubin levels were normal, and the direct Coombs test was negative. He was diagnosed with DIIHA, possibly secondary to the trimethoprim-sulfamethoxazole. The trimethoprim-sulfamethoxazole was discontinued, and 4 pints of packed

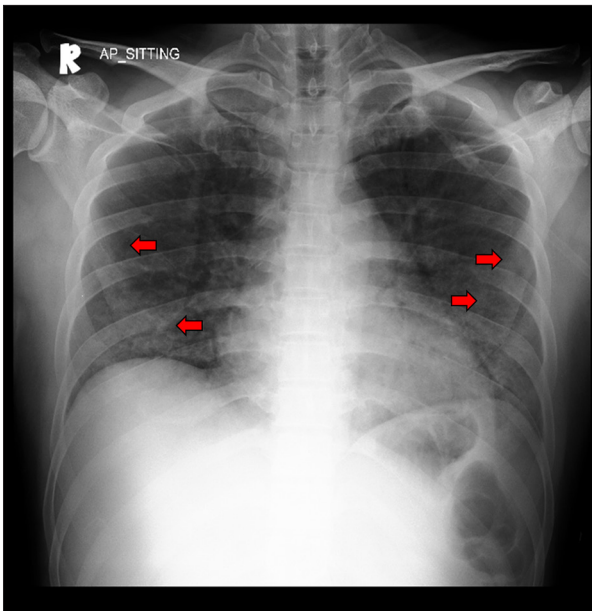


Figure 2. Chest X-Ray on July 13, 2020, showed ground-glass opacity areas with reticular changes in a perihilar distribution (red arrows).

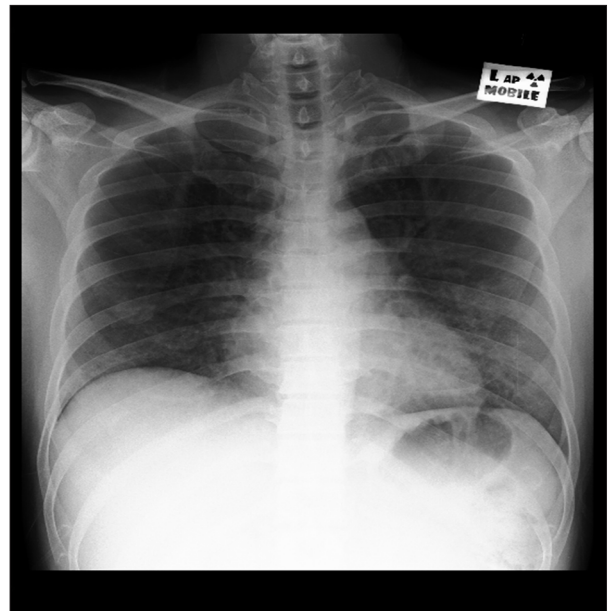


Figure 3. Chest X-Ray on August 4, 2020, showed lung improvement after 4 weeks of treatment

cells was transfused, which resulted in an increase of hemoglobin to 9.4 g/dL.

After 4 weeks of hospitalization, his symptoms improved, general conditions returned to normal, and the CXR showed a significant improvement (**Figure 3**). He started on an antiretroviral regime consisting of tenofovir, emtricitabine, and efavirenz on day 25 of admission. He was discharged in good condition and was prescribed monthly aerosolized pentamidine for PJP prophylaxis because of the DIIHA. He has since been in a good health and has kept up with his current follow-up of HIV treatment with an infectious diseases specialist in a tertiary center.

Discussion

PJP is most common in patients who have HIV. It is also common in patients with hematopoietic stem cell and solid organ transplants and cancer (particularly hematologic malignancies), and in those receiving glucocorticoids, chemotherapeutic agents, and other immunosuppressive medications [5,6]. Diagnosing PJP is challenging and requires physicians to have high clinical suspicion [7,8]. The nonspecific symptoms of PJP, including dyspnea, dry cough, and low-grade fever, can be present in any case of lung infection [9]. A CXR is initially normal at the time of presentation in as many as 39% of the cases [10]. The most common radiographic abnormalities include diffuse, bilateral, interstitial, or alveolar infiltrates, while upper lobe or segmental infiltrates, pneumothoraces, cysts, or nodules are less common [11]. The resolution of the CXR findings

usually takes 2 to 4 weeks following successful treatment [10]. Despite the difficulty, it is important to recognize the features of PJP as it has a mortality rate of up to 25%, and the percentage increases if ICU admission is required [12]. In the present case, 2 weeks elapsed between the patient's first presentation and the diagnosis of PJP, but fortunately, the patient survived.

Trimethoprim-sulfamethoxazole is the drug of choice for PJP infection [1]. Trimethoprim-sulfamethoxazole can produce an extremely uncommon DIIHA, with an estimated incidence of 1 case per million, and only 5% to 10% of patients test negative on the direct Coombs test [13,14]. There are over 130 individuals whose medications have been associated with DIIHA, but the most frequently reported medications are second- and third-generation cephalosporins, rifampicin, diclofenac, oxaliplatin, and fludarabine [15]. Our patient had trimethoprim-sulfamethoxazole exposure for 21 days before the acute onset of hemolytic anemia. The plausible diagnosis of DIIHA in our case was based on the temporal relationship between medication exposure and clinically evident anemia, along with the observed clinical and hematologic improvements following drug withdrawal.

There is a delay in making the diagnosis of PJP at presentation, which is attributed to non-disclosure regarding the risk factors concerning HIV. The issue of patients not disclosing their risk factors or medically relevant information to the treating doctors is not uncommon. Patients keep vital information from their doctors for a variety of reasons, including embarrassment, a desire to not be judged, low-risk perception, concern

about the results, and trauma from past HIV-positive experiences [16,17]. Primary care physicians, being the patient's first point of contact, have a unique chance to address these issues. Among the strategies that can be applied for the patient to speak openly during consultation are a physician's active listening, asking questions and probing appropriately, speaking simply, and creating a pleasant and comfortable atmosphere for the patient [18]. Even though our patient did not disclose his sexual activity as a risk factor for HIV in this case, the doctor made a fair clinical interpretation which expanded to include more differential diagnoses, including HIV.

Conclusions

In summary, this case highlights the challenging process taken to diagnose a typical PJP disease hidden by a normal chest

radiograph in an early stage. Our case demonstrated the importance of having high clinical suspicion and considering a wide range of differential diagnoses to request the relevant tests without offending the patient. In addition, DIIHA due to trimethoprim-sulfamethoxazole was a life-threatening complication that was managed promptly.

Department and Institution Where Work Was Done

This work was conducted at the Faculty of Medicine, Universiti Teknologi MARA, Sungai Buloh, Malaysia.

Declaration of Figures' Authenticity

All figures submitted have been created by the authors who confirm that the images are original with no duplication and have not been previously published in whole or in part.

References:

- Centers for Disease Control Prevention. Guidelines for the prevention and treatment of opportunistic infections in adults and adolescents with HIV recommendations from the Centers for Disease Control and Prevention. *MMWR Recomm Rep*. 2019;424:H1-8
- Truong J, Ashurst JV. *Pneumocystis jirovecii* pneumonia. In: StatPearls [Internet]. Treasure Island (FL): StatPearls Publishing; 2022. Available from: <https://www.ncbi.nlm.nih.gov/books/NBK482370/>
- Salzer HJF, Schäfer G, Hoenigl M, et al. Clinical, diagnostic, and treatment disparities between HIV-infected and non-HIV-infected immunocompromised patients with *Pneumocystis jirovecii* pneumonia. *Respiration*. 2018;96(1):52-65
- Fujii T, Iwamoto A, Nakamura T. Pneumocystis pneumonia in patients with HIV infection: Clinical manifestations, laboratory findings, and radiological features. *J Infect Chemother*. 2007;13(1):1-7
- Roux A, Gonzalez F, Roux M, et al. Update on pulmonary *Pneumocystis jirovecii* infection in non-HIV patients. *Med Mal Infect*. 2014;44(5):185-98
- Khan A, Muddassir K, Muthiah M, et al. A clinical dilemma: PCP in non-HIV patient. *Chest*. 2016;150(4):122A
- Sabbagh W, Darwich NS. *Pneumocystis jirovecii* pneumonia and newly diagnosed Human Immunodeficiency Virus (AIDS) in a 63-year-old woman. *Am J Case Rep*. 2018;19:927-31
- Arshad V, Iqbal N, Saleem HA, et al. Case of undiagnosed pneumocystis pneumonia (PCP). *BMJ Case Rep*. 2017;2017:29066657
- Carmona EM, Limper AH. Update on the diagnosis and treatment of *Pneumocystis pneumonia*. *Ther Adv Respir Dis*. 2011;5(1):41-59
- Boiselle PM, Crans CA Jr., Kaplan MA. The changing face of *Pneumocystis carinii* pneumonia in AIDS patients. *Am J Roentgenol*. 1999;172(5):1301-9
- Peck KR, Kim TJ, Lee MA, et al. Pneumonia in immunocompromised patients: Updates in clinical and imaging features. *Precis Future Med*. 2018;2(3):95-108
- Schmidt JJ, Lueck C, Ziesing S, et al. Clinical course, treatment and outcome of *Pneumocystis pneumonia* in immunocompromised adults: A retrospective analysis over 17 years. *Crit Care*. 2018;22(1):307
- Wu Y, Wu Yong, Ji Y, et al. Case report: Drug-induced immune haemolytic anaemia caused by cefoperazone-tazobactam/sulbactam combination therapy. *Front Med*. 2021;8:697192
- Takahashi T. Direct antiglobulin test-negative autoimmune hemolytic anaemia. *Acta Haematol*. 2018;140(1):18-19
- Hill QA, Stamps R, Massey E, et al. Guidelines on the management of drug-induced immune and secondary autoimmune, haemolytic anaemia. *Br J Haematol*. 2017;177(2):208-20
- Levy AG, Scherer AM, Zikmund-Fisher BJ, et al. Prevalence of and factors associated with patient nondisclosure of medically relevant information to clinicians. *JAMA Netw Open*. 2018;1(7):e185293
- Bedert M, Davidovich U, de Bree G, et al. Understanding reasons for HIV late diagnosis: a qualitative study among HIV-positive individuals in Amsterdam, The Netherlands. *AIDS Behav*. 2021;25(9):2898-906
- Ranjan P, Kumari A, Chakrawarty A. How can doctors improve their communication skills? *J Clin Diagnostic Res*. 2015;9(3):JE01