Department I for Internal Medicine
University Hospital of Cologne, Germany
ECMM Diamond Excellence Center

University Hospital Cologne – Management Pathway – Febrile Neutropenia

Version 10/2022
doi: 10.4126/FRL01-006438294

Neutropenia <500/µl for <10d
If MASCC (see „outpatients“ algorithm) >20, no quinolone prophylaxis, no ESBL/MRSA colonization

Neutropenia <500/µl for < 10d
e.g. lymphoma, autologous SCT, CAR-T-cell treatment, solid tumor

Neutropenia <500/µl for ≥ 10d
AML, ALL, MDS, VSAA
during induction and consolidation

***De novo* AML or ALL: Baseline chest CT [25];**
Upon admission stool screening for ESBL-producing Enterobacterales [1], screening for VRE only if patient with history of VRE [28]

Prophylaxis

Corticosteroids for > 21d, alemtuzumab, idelalisib, temozolomide + radiation or fludarabine + cyclophosphamide + rituximab (2nd line) [20]:
TMP-SMX 960 mg Mo-Wed-Fr p.o.
All others: No standard TMP-SMX prophylaxis

Autologous SCT
Prior to engraftment: No prophylaxis

From engraftment until d100:
TMP-SMX 960 mg Mo-Wed-Fr p.o.
Valacyclovir 500 mg 1-1-1

TMP-SMX 960 mg Mo-Wed-Fr p.o. [3]

AML/MDS induction, VSAA, less intensively treated AML/MDS:
Posaconazole: d1: 3 tbl. 2x/d, from d2+: 3 tbl 1x/d [4, 19]
2x weekly posaconazole TDM if: oral suspension; concomitant midostaurin/venetoclax (also midostaurin/VEN TDM); breakthrough IFI during triazole prophylaxis

AML/MDS: Comedication with **venetoclax**: **Adapt VEN dose** [26, 27]

If **posaconazole is contra-indicated** (e.g. due to vincristin): 3x/week serum galactomannan („Aspergillus antigen“) [2]

Febrile Neutropenia

Blood cultures (central + peripheral); plus further diagnostics only if **corresponding clinical signs or symptoms** (e.g. urine culture, stool PCR etc.); if **mucositis**: Oral swabs (HSV, fungi); if **abdominal symptoms** or **constipation**: Abdominal ultrasound or CT scan; if **lower respiratory tract symptoms**: High-resolution chest CT scan; if **outpatient or inpatient for <72 h**: *Legionella* and *pneumococcal* antigen in urine [7]

Treatment

Ciprofloxacin 500 mg 2x/d p.o. +
Amoxicillin/clavulanate 875+125 mg 3x/d p.o.
(if proven penicillin allergy: clindamycin 600 mg 3x/d) [21]

Consider treatment according to „Outpatients“ (see below)

Piperacillin 4 g + Tazobactam 0.5 g i.v. 3x/d [6]
If hospital-acquired pneumonia/respiratory focus or known colonization with *P. aeruginosa*: **Piperacillin 4 g + Tazobactam 0.5 g i.v. 4x/d** [29]

If **colonization with ESBL**: Meropenem 1 g i.v. 3x/d; If **colonization with MRSA**: Add vancomycin 1 g 2x/d i.v.; see also **vancomycin SOP** [1]
If **colonization with VRE**: NO empiric linezolid treatment
If blood cultures sterile or **susceptible pathogen/bacteria: step-down to first line;** except for abdominal focus

No response within 72-96h or **2nd fever episode in same neutropenia episode**

Blood cultures (central + peripheral); procalcitonin; **serial serum galactomannan** (on three consecutive days); high-resolution **chest CT within 24h** (see „Chest CT“ algorithm);
plus further diagnostics only if **corresponding clinical signs or symptoms** (e.g. urine culture, Stool-PCR); if **abdominal symptoms** or **constipation**: see “chemotherapy-associated abdominal complications“

Admission
Piperacillin 4 g + Tazobactam 0.5 g i.v. 3x/d [6]

No further change by default reasonable, consider ID consult [16]

Chest CT, if persistent fever 72-96h or **lower respiratory tract symptoms [9, 10]**

Baseline chest CT in *de novo* AML/ALL [25]

Infiltrates supicious of fungal infection

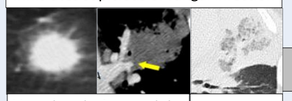

Vessel occlusion, nodule, halo, cavernous lesion or air crescent

Inverse halo



Unspecific infiltrates

No infiltrates

BAL workup:
- Inspection of resp. tract
- Bacteria + susceptibility test
- Fungi
- Atypical pneumonia panel
- Respiratory viruses
- Mycobacteria + TB-PCR
- Galactomannan
- *Aspergillus/Mucorales*-PCR

Vessel occlusion *or* **high-risk patient** (neutropenia ≥ 10d or GvHD treatment)

Mucorales detected: ID Consult and email to ***mucor@uk-koeln.de*** (see also Mucor SOP)

Aspergillus sp.

Pathogen identified

No

Yes

High probability of invasive aspergillosis or other IFD [11]: **ID Consult**

Specific treatment
ID Consult

No specific treatment
If status deteriorates
ID Consult [15]

Voriconazole (not active against Mucorales)
d1: 6 mg/kg i.v. 2x/d
d2+: 4 mg/kg i.v. 2x/d
TDM after 72hrs, and twice weekly

If triazoles are contraindicated (e.g. before/ after vinca alkaloids (7 days washout) or breakthrough infection during triazole administration) [13, 14]:
Liposomal amphotericin B 3 mg/kg/d i.v. 1x/d

If toxicity, nephropathy, hepatopathy, QT prolonged, CNS effects [12]:
Isavuconazole
d1+2: 200 mg i.v. 3x/d; d2+: 200 mg i.v. 1x/d

Repeat chest CT after 7d and 14d [22]
Response/stable disease:
Minimum 14d i.v. treatment, then switch to oral
Deterioration after d14:
Consider and evaluate biopsy

Management: EQUAL Scores [30. 31. 32]
Aspergillus | Mucormycosis | Candidemia

Outpatients

MASCC Score:

No or only mild symptoms other than fever	5 points
No hypotension	5 points
No COPD	4 points
Solid tumor **or** no previous fungal infection	4 points
No severe dehydration	3 points
Moderate symptoms other than fever	3 points
Outpatient at fever onset	3 points
Age less than 60 years	2 points

Qualified for oral treatment? [17]
MASCC Score >20
Expected neutropenia less than 10 days
No quinolone prophylaxis
No ESBL/MRSA colonization

Qualified for outpatient treatment? [18]
Can reach qualified hospital within 30 min
Is not alone at home
Did not deteriorate further in the first four hours after onset of fever
Does not require other intravenous treatment

Discharge patient
Re-admission if still febrile after 48 hours or clinical deterioration
Follow-up in outpatient department

Suspicion of sepsis

If clinical deterioration, screening for sepsis:
Whole body examination + diagnostics as mentioned above
Consider daily screening for following parameters/clinical signs:

General
- Fever
- Heart rate
- Tachypnea/ dyspnea
- GCS ↓
- Fluid balance

Organ dysfunction
- Peripheral sO2 hypoxemia
- Oliguria
- Creatinin ↑
- Bilirubin ↑
- Ileus
- DIC

Tissue
- Lactate (ven. BGA!)
- Capillary perfusion

Inflammation
- CRP, PCT
- Leukopenia/ - cytosis

Hemodynamics
- Systol. BP
- MAD
- zv sO2
- Cardiac Index

Inflammation + organ dysfunction
High suspicion of sepsis

Contact ICU/IMC team
Consider and discuss transfer of the patient

In case of shock: Start i.v. fluids (cristalloids)
Further ad hoc measures to control focus of infection not mentioned above, e.g. catheter removal

End of treatment

No pathogen identified that requires defined treatment duration
(e.g. *Staphylococcus aureus*, *Candida* sp.)

Clinical improvement

Afebrile for more than 48h and no longer neutropenic

Afebrile for 72h [23, 24]

Stop antibiotic treatment [16]

Suspicion of penicillin allergy; screen upon admission
Evaluate PEN-FAST Score
See SOP „penicilline allergy“

Chemotherapy-associated abdominal complications [8]

Fever plus abdominal pain or **fever plus constipation ≥3 days**

Abdominal ultrasound or CT;
if constipation: Abdominal overview, repeat stool examination (CDT);
if antibiotic treatment already initiated: Repeat blood cultures

- If colonized with ESBL: Switch to meropenem 1 g 3x/d i.v.
- Bland diet
- Control of symptoms if obstipation:
  - Avoid opioids
  - If platelets > 30,000/µL: Enema
  - Preferred laxative: Polyethylene glycol 3x/d
- If signs of ileus on abdominal X-ray: Gastrointestinal passage

Diarrhoea

- Repeat stool samples for CDT, culture and viral panel
- If < 72h from admission: also community-acquired pathogens (*Salmonella*, *Shigella*, *Campylobacter* spp.)
- No loperamide until infectious cause of diarrhoea wasexcluded
- Avoid high loperamide doses, alternatively: octreotide 150 µg 3x/d s.c. (increase dose up to 500 µg)

Authors: Jannik Stemler, Annika Y. Claßen, Matthias Kochanek, Gerd Fätkenheuer, Philipp Köhler, Norma Jung, Julia Fischer, Jörg J. Vehreschild, Oliver A. Cornely

References:
[1] Liss BJ Infection 2012; [2] Maertens J Blood 2001; [3] Hughes WT NEJM 1987; [4] Cornely OA NEJM 2007; [5] Cornely OA Ann Hematol 2002; [6] Reich G Br J Haematol 2005; [7] Ewig S Pneumologie 2016; [8] Vehreschild MJ Haematologica 2011; [9] Rüping MJ Drugs 2008; [10] Ruhnke M Ann Oncol 2012; [11] Donnelly JP Clin Infect Dis 2020; [12] Maertens JA Lancet 2016; [13] Cornely OA Mycoses 2011; [14] Cornely OA Clin Infect Dis 2007; [15] Vehreschild JJ Dtsch Arztebl 2012; [16] Freifeld A Clin Inf Dis 2011; [17] Vidal L Cochrane 2013; [18] Flowers C J Clin Oncol 2013; [19] Cornely OA J Antimicrob Chemother 2015; [20] Classen AY Ann Hematol 2021; [21] Freifeld A NEJM 1999; [22] Vehreschild JJ Eur Radiol 2017; [23] Le Clech L Infect Dis 2018; [24] Aguilar-Guisado M Lancet Hematol 2017; [25] Stemler J J Fungi 2020 [26] Agarwal S Clin Ther 2017 [27] Stemler J Lancet Haematol 2022 [28] Biehl LM Eurosurv 2022 [29] Dalhoff K AWMF 2017 [30] Cornely OA Mycoses 2018 [31] Koehler P J Antimicrob Chemother 2019 [32] Mellinghoff SC Mycoses 2018

UNIKLINIK KÖLN