

RESEARCH

Open Access

# Relationship between back posture and early orthodontic treatment in children



Isa Klostermann<sup>1</sup>, Christian Kirschneck<sup>2</sup>, Carsten Lippold<sup>1\*</sup>  and Sachin Chhatwani<sup>3</sup>

## Abstract

**Background:** The purpose of this study was to analyze the relationship between body posture and sagittal dental overjet in children before and after early orthodontic treatment with removable functional orthodontic appliances.

**Methods:** Angle Class II patients (mean age  $8.2 \pm 1.2$  years; 29 males and 25 females) with a distinctly enlarged overjet ( $> 9$  mm) were retrospectively examined regarding body posture parameters before and after early orthodontic treatment. In addition, changes in overjet were investigated with the aid of plaster models. Forms of transverse dysgnathism (crossbite, lateral malocclusions) and open bite cases were excluded. Body posture parameters kyphosis, lordosis, surface rotation, pelvic tilt, pelvic torsion and trunk imbalance were analyzed by means of rasterstereographical photogrammetry to determine, if the orthodontic overjet correction is associated with specific changes in posture patterns.

**Results:** In nearly all patients an overjet correction and an improvement regarding all body posture and back parameters could be noted after early orthodontic treatment. Overjet reduction ( $-3.9 \text{ mm} \pm 2.1 \text{ mm}$ ) and pelvic torsion ( $-1.28^\circ \pm 0.44^\circ$ ) were significantly ( $p < 0.05$ ) and moderately correlated ( $R = 0.338$ ) with no significant associations found for the other posture and back parameters ( $p > 0.05$ ).

**Conclusion:** Overjet reduction during early orthodontic treatment may be associated with a detectable effect on pelvic torsion.

**Keywords:** Early orthodontic treatment, Body posture, Rasterstereography, Fränkel type II appliance

## Background

A correlation of body posture and craniofacial morphology has been the focus of investigation in many studies. Especially since the 1980's publications about this topic have increased [1]. Some studies have shown some, albeit sometimes minor, influences [2–6], while other studies have found no impact of orthodontics on body posture [7–11].

The subject of these studies becomes increasingly more important considering interdisciplinary treatment combining orthopedics and orthodontics [4]. Because of the functional connection between the stomatognathic

system and the cervical spine, these two fields of medicine are inevitably linked together [12].

Early treatment in children with severe malocclusion, especially of Angle Class II type, could not only prevent incisor trauma, but also have a positive influence on potential orthopedic malformations [13]. There is no general need for patients with Angle Class I, II, III malocclusion to be treated interdisciplinarily. Only patients with an asymmetry of the jaw should undergo interdisciplinary treatment [5].

A growing number of patients with spinal deformities seek orthodontic treatment to enhance body posture [11]. But due to currently lacking evidence regarding associations between disorders of the masticatory system and postural imbalances, patients should avoid irreversible and expensive treatments, if these treatments are

\* Correspondence: [carstenlippold@yahoo.de](mailto:carstenlippold@yahoo.de)

<sup>1</sup>Department of Orthodontics, University of Muenster, Waldeyerstraße 30, 48149 Muenster, Germany

Full list of author information is available at the end of the article



© The Author(s). 2021 **Open Access** This article is licensed under a Creative Commons Attribution 4.0 International License, which permits use, sharing, adaptation, distribution and reproduction in any medium or format, as long as you give appropriate credit to the original author(s) and the source, provide a link to the Creative Commons licence, and indicate if changes were made. The images or other third party material in this article are included in the article's Creative Commons licence, unless indicated otherwise in a credit line to the material. If material is not included in the article's Creative Commons licence and your intended use is not permitted by statutory regulation or exceeds the permitted use, you will need to obtain permission directly from the copyright holder. To view a copy of this licence, visit <http://creativecommons.org/licenses/by/4.0/>. The Creative Commons Public Domain Dedication waiver (<http://creativecommons.org/publicdomain/zero/1.0/>) applies to the data made available in this article, unless otherwise stated in a credit line to the data.

aimed at correcting postural imbalances or spinal curvature alteration [14].

Different devices and procedures are used to investigate correlations between the masticatory system and body posture like postural platforms, rasterstereography, surface electromyography and kinesiography [7]. März et al. found some indications of a relationship when investigating 44 patients in seven different mandible positions and optically scanning body posture with the Diers formetric 4D system [15]. The observed different posture parameters could have arisen due to a neuromuscular compensation mechanism [7, 15]. Due to current shortcomings in scientific evidence, this topic is very interesting, considering the fact that changes in posture or the craniomandibular system may affect each other [16].

Deformities of interest in interdisciplinary orthodontic and orthopedic treatment are especially the two most frequent spinal diseases in form of scoliosis and Scheuermann's disease that in particular arise during childhood [17, 18]. Radiographs were used in the past for the measurement of scoliotic deformities, but due to the required amount of X-ray images during this procedure and thereby high radiation exposure of the patient, video rasterstereography became a popular alternative. This technique was developed in the 1980's by Hierholzer and Drerup and is a three-dimensional analysis of the back surface. With only one measurement, a 3D footage of the patients' back can be analyzed and also edited digitally. Therefore it is a useful addition for long-term controls for patients with spine deformities [19].

The aim of this study was to analyze the relationship between sagittal back contour, posture and craniofacial parameters in children before and after early orthodontic treatment with removable appliances with optical 3D back shape measurements.

As a null hypothesis it assumed that there is no difference in body posture before and after early orthodontic treatment with removable appliances.

## Methods

Sample size was determined a priori with G\*Power (Heinrich Heine University, Duesseldorf, Germany) for an effect size of 0.5, an alpha level of 0.05 and a power of 80%. The calculation showed that a minimum of 28 patients was needed for this study.

The procedure of optical spine analysis is based on footage of the back with simultaneous projection of stripes onto the back surface. Due to the curvature of the projected stripes, a pattern arises and with three anatomically fixed points, the vertebra prominens and a dimple at the left and right side at the height of the sacrum, a model of the back can be generated using a triangulation method [20–22]. The digitally plotted

model is like a visual plaster cast of the back of the patient.

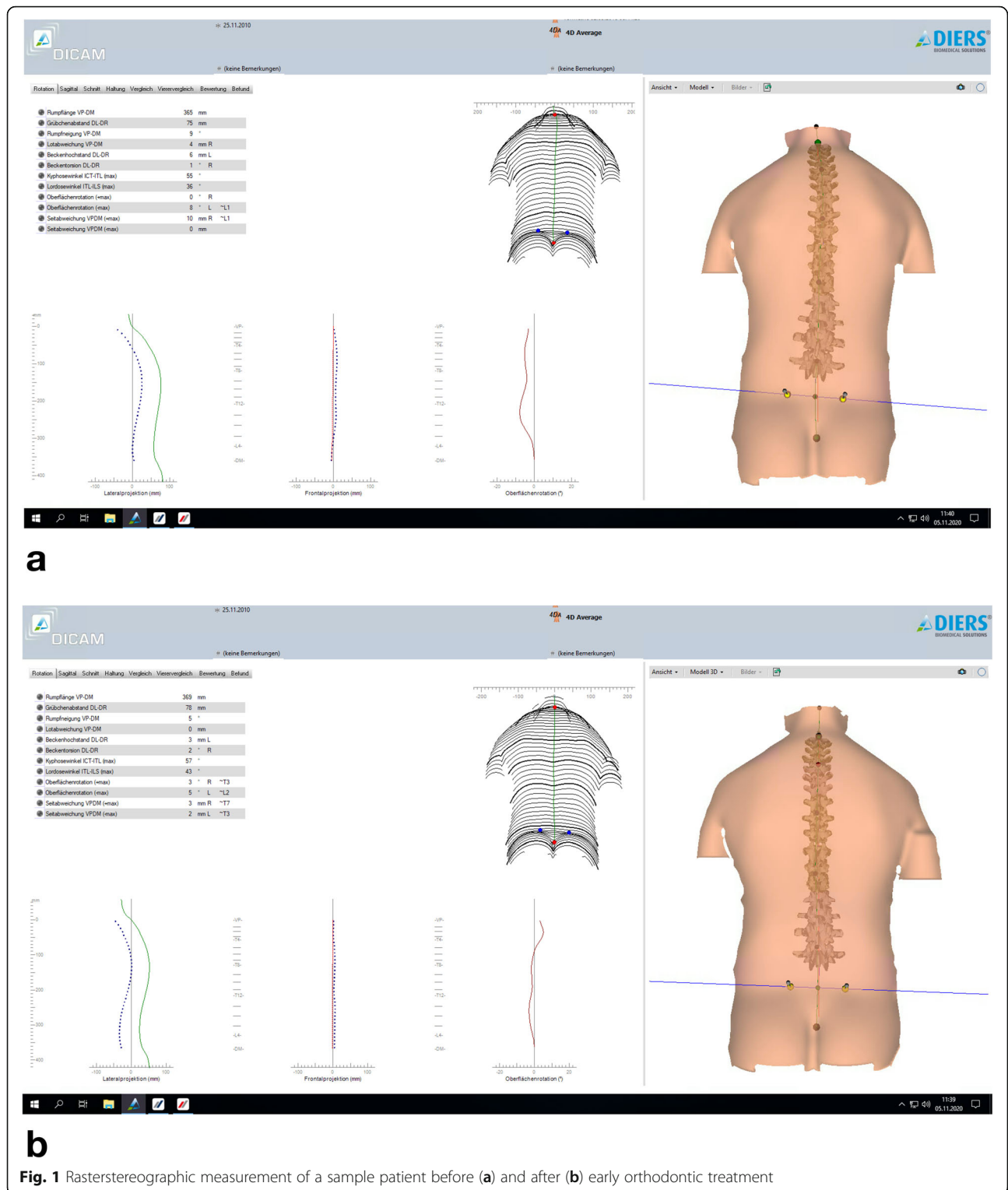
Fifty-four children (29 male, 25 female) at the age of 4.3–10.7 years, who were treated between 2008 and 2017 in an orthodontic practice and presenting mandibular retrognathia (Angle-Class II, corresponding leading symptoms), were retrospectively analyzed before (T1) and after (T2) early orthodontic treatment using rasterstereography (Diers formetric 4D, Diers International, Schlangenbad, Germany). Patients with syndromes, cleft lip and or cleft palate, forms of transverse dysgnathism (crossbite, lateral malocclusions), open bite and long-term medication or systemic diseases like diabetes mellitus were excluded. Patients with significant obesity were also excluded because of limitations regarding the rasterstereographic measurement method applied.

During rasterstereographic measurement (Fig. 1), the patients stood in a relaxed position and did not pause breathing, so that the individual position could be measured. They were barefoot and only wearing undergarment, thus there were no disturbing influences by clothing. Further details regarding the procedure of rasterstereography used in this study and determined outcome parameters can be found in a pilot study by März et al. [15]. The parameters kyphosis, lordosis, surface rotation, pelvic tilt, pelvic torsion, trunk imbalance were examined to analyze posture and back shape before (T1) and after (T2) early orthodontic treatment.

Incisor overjet was investigated with the aid of plaster models and a manual caliper (Muenchner model, Dentaurum, Ispringen, Germany) at treatment times T1 and T2, in the sagittal plane of the most prominent labial upper incisor as described in Meštrović et al. [23].


Early orthodontic treatment was performed with a Fränkel type II removable appliance (Fig. 2 a, b). Patients were instructed to wear the appliance at least for 3 h a day and full time at night. The effectiveness of the Fränkel type II appliance in early orthodontic treatment has been shown before [24].

Statistical analysis was performed using the program IBM® SPSS® Statistics 26 (IBM, Armonk, NY, USA). Descriptive-exploratory data analysis was conducted to calculate the arithmetic mean (M), standard deviation (SD), 95% confidence interval (CI), minimum (Min) and maximum (Max). For posture and back parameters the median (MD) was calculated with 95% CI. Normal distribution of the individual parameters was assessed by using Kolmogorov-Smirnov test. For analytical-statistical data analysis of paired samples, non-parametric, dependent Wilcoxon signed ranks tests were used. To check for possible correlations between the degree of overjet change (reduction) and posture and back parameters, a two-sided correlation analysis according to Spearman was conducted, where  $R > 0.5 / 0.3 / 0.1$



according to Cohen [25] corresponds to a strong, moderate or low correlation. The significance level ( $\alpha$ -error) was set to  $p \leq 0.05$ .

The study was approved by the local ethics committee in Münster, Westfalen-Lippe, Germany with the registration number 2018-340-f-S.



**Fig. 2 a, b:** Fränkel type II appliance **a)** frontal view **b)** lateral view (Photos by Prof. Dr. Carsten Lippold)

**Results**

Mean patient age ( $\pm$  SD) at the time of measurement T1 was  $8.2 \pm 1.2$  years and at the end of treatment T2  $10.1 \pm 1.3$  years. Mean treatment time of early orthodontic treatment was  $1.8 \pm 0.5$  years (Table 1).

Mean overjet measured at the beginning of treatment (T1) was  $11.1 \text{ mm} \pm 1.8 \text{ mm}$ . From T1 to T2 mean correction of overjet was  $-3.9 \text{ mm} \pm 2.1 \text{ mm}$ . This led to a mean overjet of  $7.2 \text{ mm} \pm 2.1 \text{ mm}$  at the end of early orthodontic treatment T2 (Table 1). In one patient case overjet increased by 0.5 mm from 9.5 mm to 10 mm.

Descriptive statistics of back and posture parameters at T1, T2 and of their respective changes from T1 to T2 can be seen in Table 2.

Kolmogorov-Smirnov tests revealed that not all parameters were normally distributed ( $p < 0.05$ ). Paired, dependent Wilcoxon tests showed that besides age ( $p < 0.001$ ) the amount of overjet measured differed significantly at end of treatment (T2) from the start of treatment (T1) ( $p < 0.001$ ) (Table 3).

All postural parameters also changed from T1 to T2: kyphotic angle ( $-0.69^\circ \pm 0.79^\circ$ ), lordotic angle ( $-1.52^\circ \pm 0.98^\circ$ ), pelvic tilt ( $-0.74 \text{ mm} \pm 0.76 \text{ mm}$ ), pelvic torsion ( $-1.28^\circ \pm 0.44^\circ$ ), trunk imbalance ( $-4.91 \text{ mm} \pm 1.25 \text{ mm}$ ), maximum ( $-0.41^\circ \pm 0.9^\circ$ ) and minimum ( $-1.07^\circ \pm 0.66^\circ$ ) surface rotation showed a reduction in general,

but no significant differences between T1 and T2 (Tables 2 and 3).

A significant correlation according to Spearman’s rho correlation test was found between change of overjet from T1 to T2 and pelvic torsion change from T1 to T2 (Table 4, Fig. 3).

**Discussion**

At the beginning of the twenty-first century a huge increase of interest in the topic of dental and orthopedic associations could be noted [1]. Medical awareness increased in recent years. Even though influence of dental occlusion on body balance is debated controversially some authors conclude that the afferent signals of the dental occlusion may have an impact on body balance [26]. Ohlendorf et al. also reported that a temporarily manipulated dental occlusion affects the position of the spine but questioned its clinical effect [27]. Nowadays not only children receive orthodontic treatment, but also adults with spinal abnormalities seek help from orthodontists [11]. The aim of this study was to determine, whether different orthopedic posture patterns are associated with a correction of the patients’ overjet by early orthodontic treatment. The method used in this study was rasterstereography with 4D measurement.

**Table 1** Descriptive statistics of age and overjet at T1, T2 and changes from T1 – T2

Age in years	n	M	SD	95% CI (low – high)	MD	25% Perc	75% Perc	Min	Max
T1	54	8.2	1.2	7.9–8.6	8.3	7.3	9.2	4.3	10.7
T2	54	10.1	1.3	9.7–10.4	10.1	9.0	10.9	6.1	13.1
treatment time T1 – T2	54	1.8	0.5	1.7–1.9	1.8	1.6	1.9	0.8	3.5
Overjet in mm	n	M	SD	95% CI (low – high)	MD	25% Perc	75% Perc	Min	Max
T1	54	11.1	1.8	10.6–11.6	10.5	10.0	12.0	8.0	18.0
T2	54	7.2	2.1	6.6–7.7	7.0	6.0	8.5	3.0	14.0
overjet correction T1 – T2	54	-3.9	2.1	-4.5 – -3.3	-3.5	-4.6	-2.5	-11.0	0.5

M arithmetic mean, SD standard deviation, CI confidence interval, MD Median, Perc Percentile, Min Minimum, Max Maximum

**Table 2** Descriptive statistics of posture and back parameters at T1, T2 and their respective changes from T1 to T2

Posture/back parameter	n	M	SD	MD	95% CI (low – high)	Min	Max
kyphotic angle in ° at T1	54	42.89	0.94	42.5	40.0–45.0	28.0	61.0
kyphotic angle in ° at T2	54	42.2	0.79	42.0	41.0–45.0	27.0	54.0
kyphotic angle change in ° from T1 to T2	54	–0.69	0.79	–1.0	–1.0 – 3.0	–13.0	14.0
lordotic angle in ° at T1	54	35.69	1.03	35.0	32.0–39.0	23.0	48.0
lordotic angle in ° at T2	54	34.17	1.06	33.0	31.0–37.0	19.0	54.0
lordotic angle change in ° from T1 to T2	54	–1.52	0.98	–1.0	–4.0 – 1.0	–19.0	12.0
pelvic tilt in mm at T1	54	3.17	0.39	3.0	3.0–6.0	0.0	15.0
pelvic tilt in mm at T2	54	3.65	0.44	3.0	3.0–6.0	0.0	15.0
pelvic tilt change in mm from T1 to T2	54	–0.74	0.76	0.0	0.0–3.0	–27.0	12.0
pelvic torsion at T1 in °	54	2.46	0.25	2.0	2.0–3.0	0.0	7.0
pelvic torsion at T2 in °	54	2.44	0.23	2.0	2.0–3.0	0.0	6.0
pelvic torsion change in ° from T1 to T2	54	–1.28	0.44	–1.0	–1.0 – 0.0	–11.0	5.0
trunk imbalance in mm at T1	54	6.8	0.86	5.5	3.0–8.0	0.0	32.0
trunk imbalance in mm at T2	54	5.67	0.54	5.0	4.0–7.0	0.0	22.0
trunk imbalance change in mm from T1 to T2	54	–4.91	1.25	–4.5	–8.0 – –1.0	–39.0	17.0
max surface rotation at T1 in °	54	5.52	0.6	5.0	3.0–7.0	0.0	16.0
max surface rotation at T2 in °	54	5.59	0.6	5.0	3.0–7.0	0.0	14
max surface rotation change in ° from T1 to T2	54	–0.41	0.9	0.0	–2.0 – 2.0	–18.0	12.0
min surface rotation in ° at T1	54	5.46	0.67	4.0	3.0–6.0	0.0	25.0
min surface rotation in ° at T2	54	5.31	0.63	4.5	3.0–6.0	0.0	22.0
min surface rotation change in ° from T1 to T2	54	–1.07	0.66	–1.0	–2.0 – 2.0	–15.0	10.0

M arithmetic mean, SD standard deviation, MD Median, CI confidence interval, Min Minimum, Max Maximum

During 3D measurements, a recording of the back shape is made in only 0.25 s, comparable to a conventional X-ray image [10]. But even when standing still, involuntary movements of the body like breathing have an impact on the surface of the body and thereby the rasterstereographic measurement. During 4D measurements optional single shootings are made and the impact of involuntary movements can be minimized [21]. An advantage of the 4D measurement is the reliability under dynamic conditions in comparison to a single measurement [19]. It seems that this method is appropriate for assessment of posture and back parameters in this study [28].

Compared to a multicenter, randomized-controlled trial investigating the overall dental and skeletal changes in early orthodontic treatment, the patients in this study were approximately 1.5 years younger ( $9.7 \pm 0.98$  years

compared to  $8.2 \pm 1.2$  years) [29]. In the same study mean change of overjet was higher  $-6.63$  mm (95% CI  $-7.28$  mm –  $-5.98$  mm) than in our study  $-3.9$  mm (95% CI  $-4.5$  –  $-3.3$  mm). The appliance used by that study group was a Twin Block appliance which was used in 89 patients [29]. Tulloch et al. showed less overjet reduction than observed in our study after early orthodontic treatment with functional appliances ( $-2.66$  mm  $\pm$   $1.81$  mm) [30]. A study by Toth and McNamara investigating 40 patients treated with Fränkel type II appliances ( $-3.1 \pm 1.5$  mm) and 40 patients with Twin Block appliances ( $-3.6 \pm 2.7$  mm) showed no significant difference in overjet reduction after 16 months between both appliances [31]. Thus the overjet reduction in this study is in concordance with literature, as well as treatment duration for early orthodontic treatment ( $1.4 \pm 0.57$  years) [32]. Probable explanations for discrepancies in results therefore

**Table 3** Wilcoxon signed ranks test for back/posture parameters, overjet and age comparing at measurement times T1 and T2

	kyphotic angle	lordotic angle	pelvic tilt	pelvic torsion	trunk imbalance	max surface rotation	min surface rotation	overjet	age
Z	–0.954 <sup>b</sup>	–1.416 <sup>b</sup>	–0.967 <sup>c</sup>	–0.079 <sup>b</sup>	–0.887 <sup>b</sup>	–0.031 <sup>c</sup>	–0.175 <sup>b</sup>	–6.388 <sup>b</sup>	–6.396 <sup>c</sup>
Asymp. Sig. (2-tailed)	0.34	0.157	0.334	0.937	0.375	0.975	0.861	0.000***	0.000***

Wilcoxon signed ranks test b) based on positive ranks c) based on negative ranks \*\*\*) significance at level  $p < 0.001$

**Table 4** Spearman correlation of change of overjet T1 – T2 and changes of the individual back/posture parameters T1 – T2

Change of overjet T1 – T2 in correlation with	n	Correlation Coefficient rho	Sig. (2-tailed)
Δ kyphotic angle T1 – T2	54	0.066	0.634
Δ lordotic angle T1 – T2	54	0.000	0.997
Δ pelvic tilt T1 – T2	54	0.136	0.325
Δ pelvic torsion T1 – T2	54	0.338	0.012*
Δ trunk imbalance T1 – T2	54	–0.148	0.285
Δ surface rotation max T1 – T2	54	0.198	0.151
Δ surface rotation min T1 – T2	54	–0.132	0.343

Δ) change of \*) Correlation significant at level  $p < 0.05$  (2-tailed)

might be differing patient motivation or compliance compared to our study.

This study shows a moderate correlation between sagittal incisor overjet and orthopedic parameters with a significant correlation observed for a reduced overjet and pelvic torsion ( $p < 0,012$ ). Still, the results of this study are in line with other studies that have found no strong connection of back and posture parameters and orthodontic treatment, as no significant differences were found for pelvic torsion from T1 to T2.

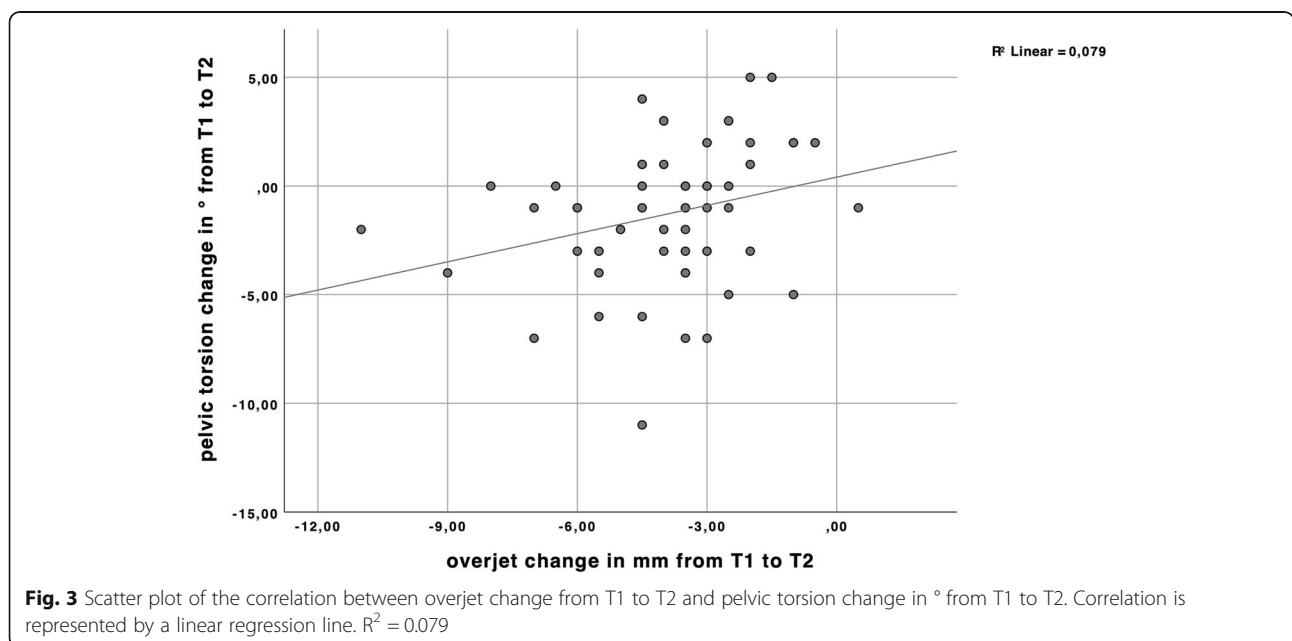
Lippold et al. investigated the relationship between orthopedic findings and craniofacial morphology showing a correlation of craniofacial parameters and thoracic, lordotic and pelvic inclination. They concluded that there is evidence of relations between the body posture in the upper area (cervical to thoracal region) and the craniofacial morphology [4].

In contrast a detectable correlation between dental occlusion and body posture not found by Perinetti [8, 33]. The body’s neuromuscular and anatomical balancing

mechanisms may be the reason, why no differences were discovered [8, 15]. It could be that the immediate change in pelvic torsion after overjet correction is an accidental finding, but also it could be thought of that pelvic torsion change plays a role in anatomical balancing.

A study supporting dental and orthopedic associations shows that orthopedic abnormalities are more common in children (3,5–6,8 years) with an Angle class II than in Angle class I. Scoliotic abnormalities are found in 21.1% of children with Angle class II and hypotonic body posture is also common (52.6%). This shows that orthodontic treatment should not be limited to an extremely positioned frontal incisor, but early treatment may also prevent orthopedic misdevelopment in Angle class II dysgnathia [13].

Parrini et al. described modifications of kyphotic angle, upper thoracic inclination and pelvic inclination after 6 months of orthodontic treatment with aligners and thereby showed the influence of orthodontics or change of vertical dimension on body posture [34].



Kamal and Fida have reported that craniocervical posture after Twin Block therapy is more upright [35]. They, however, derived their findings from lateral cephalograms, which did not correspond to natural head position at rest.

The differing results in literature show the importance of further studies to investigate this topic as clear evidence is currently still missing. Future studies should not only investigate immediate effects of orthodontic intervention on body posture, but also possible long-term effects.

Postural control is very complex and is also influenced by visual, vestibular and proprioceptive systems [36]. Due to its multifactorial occurrence it is difficult to emphasize on individual aspects. Further limitations of this study comprise its retrospective and correlative character, which does not allow assessments of causality, as well as the absence of a control group. With regard to overjet correction it can be said that it was not solely of skeletal, but also of dental origin [31]. It would be of interest to investigate the influence of surgical treatment in adults on body posture as the skeletal changes are higher. Future studies should investigate correlations of skeletal changes to body posture especially in the long-term.

Although a minor correlation of overjet reduction and pelvic torsion could be seen in this study the null hypothesis is to be accepted.

## Conclusion

In this study, no significant differences of back and posture patterns were found after early orthodontic treatment with removable appliances. A decrease of overjet was moderately correlated to a change of pelvic torsion. This immediate, but minor presumable influence of orthodontics on orthopedics could lead to further longitudinal studies pursuing this interdisciplinary approach.

## Acknowledgements

Not applicable.

## Authors' contributions

IK assessed the data, performed the literature research and wrote the present article. CK contributed to the statistical analysis and revised the manuscript. CL designed and supervised the study. SC assisted in the setup of the study and performed the statistical analysis, manuscript revision. The authors read and approved the final manuscript.

## Funding

This research did not receive any specific grant from funding agencies in the public, commercial or not-for-profit sectors. Open Access funding enabled and organized by Projekt DEAL.

## Availability of data and materials

All data is available upon request.

## Ethics approval and consent to participate

The study is in accordance with the ethical standards of the institutional and/or national ethics committee and with the 1964 Helsinki declaration and

its later amendments or comparable ethical standards. The study was approved by the ethics committee of the medical council of Westphalia-Lippe and the University of Muenster (2018–340-f-5). Informed consent for the anonymized usage of patient data and records was obtained from all study participants.

## Competing interests

The authors report no financial or other conflict of interest relevant to this article, which is the intellectual property of the authors. The authors declare that they have no competing interests.

## Author details

<sup>1</sup>Department of Orthodontics, University of Muenster, Waldeyerstraße 30, 48149 Muenster, Germany. <sup>2</sup>Department of Orthodontics, University Medical Centre of Regensburg, Franz-Josef-Strauss-Allee 11, 93053 Regensburg, Germany. <sup>3</sup>Department of Orthodontics, School of Dentistry, Faculty of Health, Witten/Herdecke University, Alfred-Herrhausen Str. 45, 58455 Witten, Germany.

Received: 29 June 2020 Accepted: 15 January 2021

Published online: 05 February 2021

## References

- Hanke BA, Motschall E, Turp JC. Association between orthopedic and dental findings: what level of evidence is available? *J Orofac Orthop*. 2007;68(2):91–107.
- Gangloff P, Louis JP, Perrin PP. Dental occlusion modifies gaze and posture stabilization in human subjects. *Neurosci Lett*. 2000;293(3):203–6.
- Baldini A, Nota A, Tripodi D, Longoni S, Cozza P. Evaluation of the correlation between dental occlusion and posture using a force platform. *Clinics (Sao Paulo)*. 2013;68(1):45–9.
- Lippold C, Danesh G, Schilgen M, Drerup B, Hackenberg L. Relationship between thoracic, lordotic, and pelvic inclination and craniofacial morphology in adults. *Angle Orthod*. 2006;76(5):779–85.
- Lippold C, Ehmer U, van den Bos L. Beziehungen zwischen kieferorthopädischen und orthopädischen Befunden. *Man Med*. 2000;38(6):346–50.
- Solow B, Sonnesen L. Head posture and malocclusions. *Eur J Orthodontics*. 1998;20(6):685–93.
- Manfredini D, Castrolforio T, Perinetti G, Guarda-Nardini L. Dental occlusion, body posture and temporomandibular disorders: where we are now and where we are heading for. *J Oral Rehabil*. 2006;33(6):463–71.
- Perinetti G. Dental occlusion and body posture: no detectable correlation. *Gait Posture*. 2006;24(2):165–8.
- Lippold C, Moiseenko T, Drerup B, Schilgen M, Végh A, Danesh G. Spine deviations and orthodontic treatment of asymmetric malocclusions in children. *BMC Musculoskelet Disord*. 2012;13(1):151.
- Lippold C, Danesh G, Schilgen M, Drerup B, Hackenberg L. Sagittal jaw position in relation to body posture in adult humans—a rasterstereographic study. *BMC Musculoskelet Disord*. 2006;7(1):8.
- Langella F, Fusini F, Rossi G, Villafañe JH, Migliaccio N, Donzelli S, et al. Correction to: Spinal deformity and malocclusion association is not supported by high-quality studies: results from a systematic review of the literature. *Eur Spine J*. 2019. <https://doi.org/10.1007/s00586-019-05896-4>
- Korbmacher H, Eggert-Stroeder G, Koch L, Kahl-Nieke B. Correlations between dentition anomalies and diseases of the of the postural and movement apparatus—a literature review. *Journal of orofacial orthopedics= Fortschritte der Kieferorthopädie: Organ/official journal Deutsche Gesellschaft für Kieferorthopädie*. 2004;65(3):190–203.
- Lippold C, van den Bos L, Hohoff A, Danesh G, Ehmer U. Interdisciplinary study of orthopedic and orthodontic findings in pre-school infants. *J Orofac Orthop/Fortschritte der Kieferorthopädie*. 2003;64(5):330–40.
- Michelotti A, Buonocore G, Manzo P, Pellegrino G, Farella M. Dental occlusion and posture: an overview. *Prog Orthod*. 2011;12(1):53–8.
- März K, Adler W, Matta R-E, Wolf L, Wichmann M, Bergauer B. Can different occlusal positions instantaneously impact spine and body posture? *J Orofac Orthop/Fortschritte der Kieferorthopädie*. 2017;78(3):221–32.
- Khan MT, Verma SK, Maheshwari S, Zahid SN, Chaudhary PK. Neuromuscular dentistry: occlusal diseases and posture. *J Oral Biol Craniofac Res*. 2013;3(3):146–50.

17. Liljenqvist U, Halm H, Hierholzer E, Drerup B, Weiland M. Die dreidimensionale Oberflächenvermessung von Wirbelsäulendeformitäten anhand der Videorasterstereographie. *Z Orthop Ihre Grenzgeb.* 1998;136(01): 57–64.
18. Segatto E, Lippold C, Végh A. Craniofacial features of children with spinal deformities. *BMC Musculoskelet Disord.* 2008;9(1):169.
19. Betsch M, Wild M, Jungbluth P, Hakimi M, Windolf J, Haex B, et al. Reliability and validity of 4D rasterstereography under dynamic conditions. *Comput Biol Med.* 2011;41(6):308–12.
20. Drerup B. Rasterstereographic measurement of scoliotic deformity. *Scoliosis.* 2014;9(1):22.
21. Betsch M, Wild M, Rath B, Tingart M, Schulze A, Quack V. Strahlenfreie Diagnostik bei Skoliosen. *Orthopade.* 2015;44(11):845–51.
22. Drerup B, Ellger B, Zu Bentrup Meyer F, Hierholzer E. functional rasterstereographic images. A new method for biomechanical analysis of skeletal geometry. *Der Orthopade.* 2001;30(4):242–50.
23. Meštrović S, GABRIĆ PANDURIĆ D, ANIĆ MILOŠEVIĆ S, Ribarić D. Risk factors of traumatic injuries to the upper incisors. *Acta Stomatologica Croatica.* 2008;42(1):3–10.
24. Ghafaria J, Shoferb F, Jacobsson-Hunta U, Markowitzc D, Lasterb L. Headgear versus function regulator in the early treatment of class II, division 1 malocclusion: a randomized clinical trial. *Am J Orthod Dentofac Orthop.* 1998;113(1):51–61.
25. Cohen J. A power primer. *Psychol Bull.* 1992;112(1):155.
26. Julià-Sánchez S, Álvarez-Herms J, Burtscher M. Dental occlusion and body balance: a question of environmental constraints? *J Oral Rehabil.* 2019;46(4): 388–97.
27. Ohlendorf D, Seebach K, Hoerzer S, Nigg S, Kopp S. The effects of a temporarily manipulated dental occlusion on the position of the spine: a comparison during standing and walking. *Spine J.* 2014;14(10):2384–91.
28. Krott NL, Wild M, Betsch M. Meta-analysis of the validity and reliability of rasterstereographic measurements of spinal posture. *Eur Spine J.* 2020:1–10.
29. O'Brien K, Wright J, Conboy F, Sanjie Y, Mandall N, Chadwick S, et al. Effectiveness of early orthodontic treatment with the twin-block appliance: a multicenter, randomized, controlled trial. Part 1: dental and skeletal effects. *Am J Orthod Dentofac Orthop.* 2003;124(3):234–43.
30. Tulloch JC, Phillips C, Koch G, Proffit WR. The effect of early intervention on skeletal pattern in class II malocclusion: a randomized clinical trial. *Am J Orthod Dentofac Orthop.* 1997;111(4):391–400.
31. Toth LR, McNamara JA Jr. Treatment effects produced by the twin-block appliance and the FR-2 appliance of Fränkel compared with an untreated class II sample. *Am J Orthod Dentofac Orthop.* 1999;116(6):597–609.
32. O'Brien K, Wright J, Conboy F, Appelbe P, Davies L, Connolly I, et al. Early treatment for class II division 1 malocclusion with the twin-block appliance: a multi-center, randomized, controlled trial. *Am J Orthod Dentofac Orthop.* 2009;135(5):573–9.
33. Perinetti G, Contardo L, Silvestrini-Biavati A, Perdoni L, Castaldo A. Dental malocclusion and body posture in young subjects: a multiple regression study. *Clinics.* 2010;65(7):689–95.
34. Parrini S, Comba B, Rossini G, Ravera S, Cugliari G, De Giorgi I, et al. Postural changes in orthodontic patients treated with clear aligners: a rasterstereographic study. *J Electromyogr Kinesiol.* 2018;38:44–8.
35. Kamal AT, Fida M. Evaluation of cervical spine posture after functional therapy with twin-block appliances: a retrospective cohort study. *Am J Orthod Dentofac Orthop.* 2019;155(5):656–61.
36. Fitzpatrick R, McCloskey D. Proprioceptive, visual and vestibular thresholds for the perception of sway during standing in humans. *J Physiol.* 1994; 478(1):173–86.

## Publisher's Note

Springer Nature remains neutral with regard to jurisdictional claims in published maps and institutional affiliations.

**Ready to submit your research? Choose BMC and benefit from:**

- fast, convenient online submission
- thorough peer review by experienced researchers in your field
- rapid publication on acceptance
- support for research data, including large and complex data types
- gold Open Access which fosters wider collaboration and increased citations
- maximum visibility for your research: over 100M website views per year

**At BMC, research is always in progress.**

Learn more [biomedcentral.com/submissions](https://biomedcentral.com/submissions)

